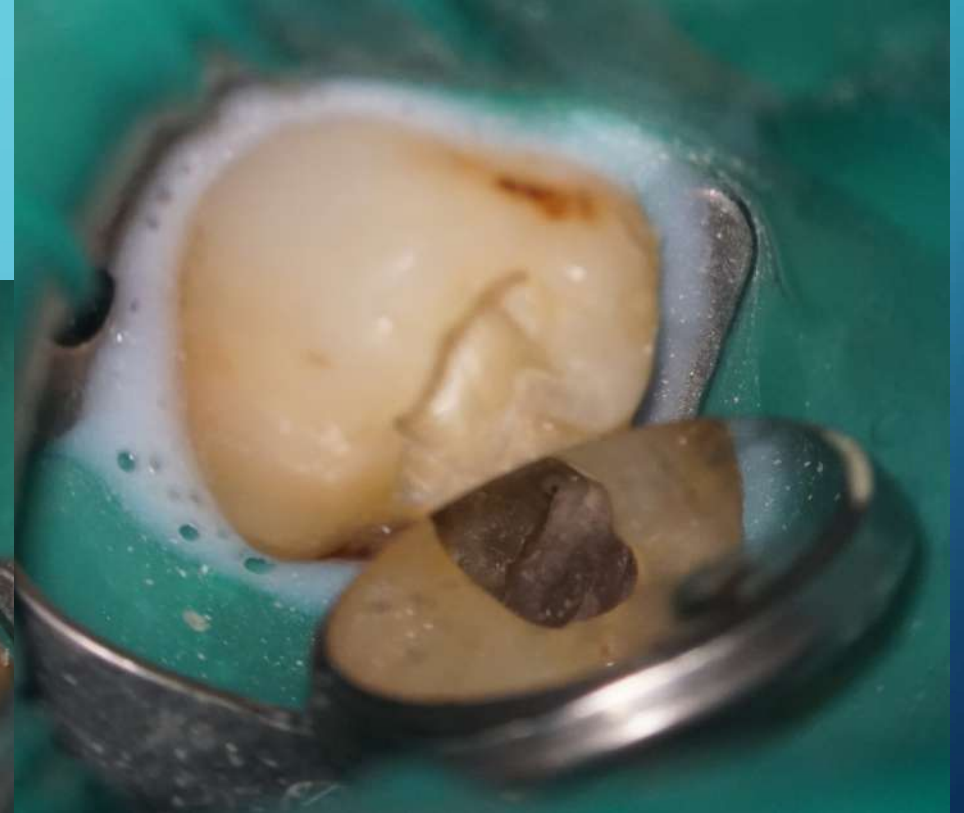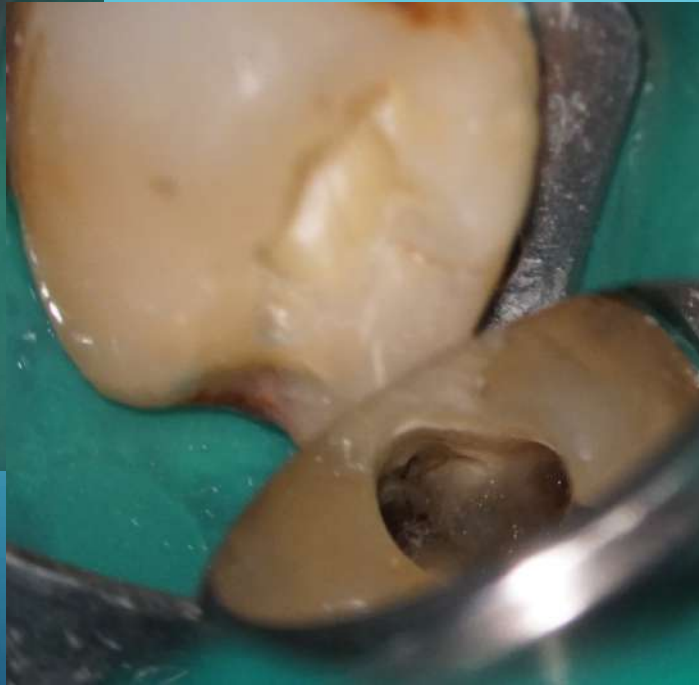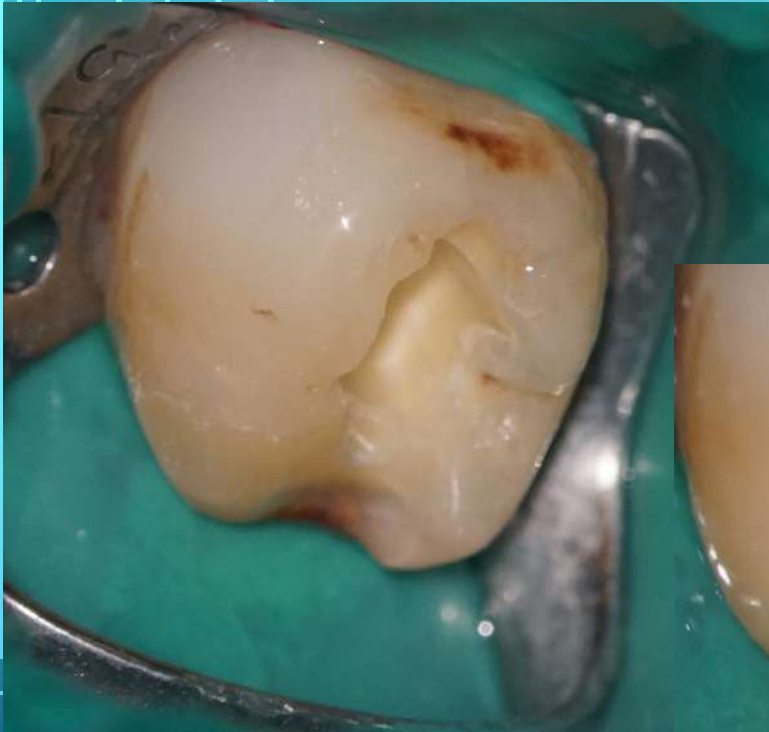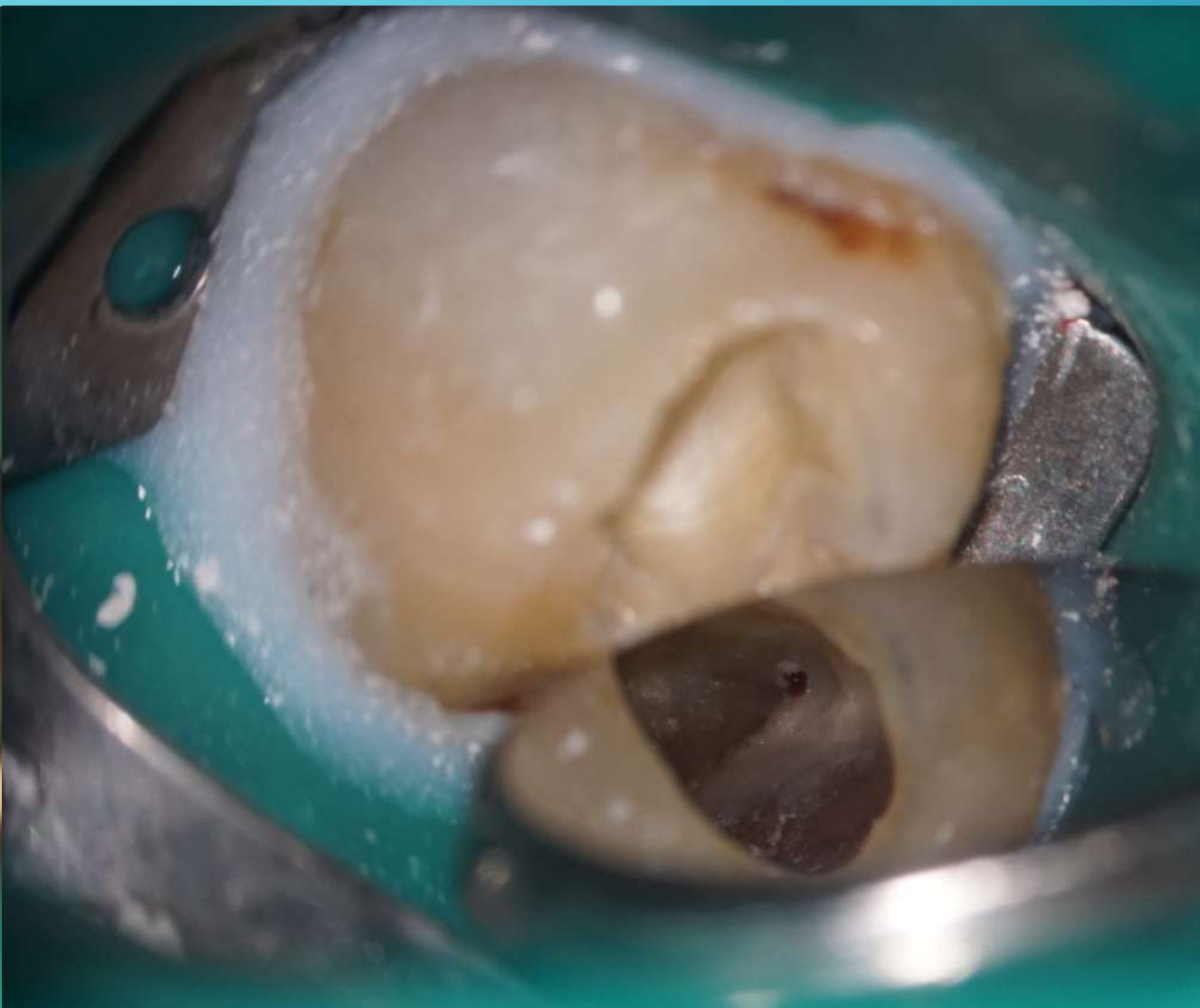
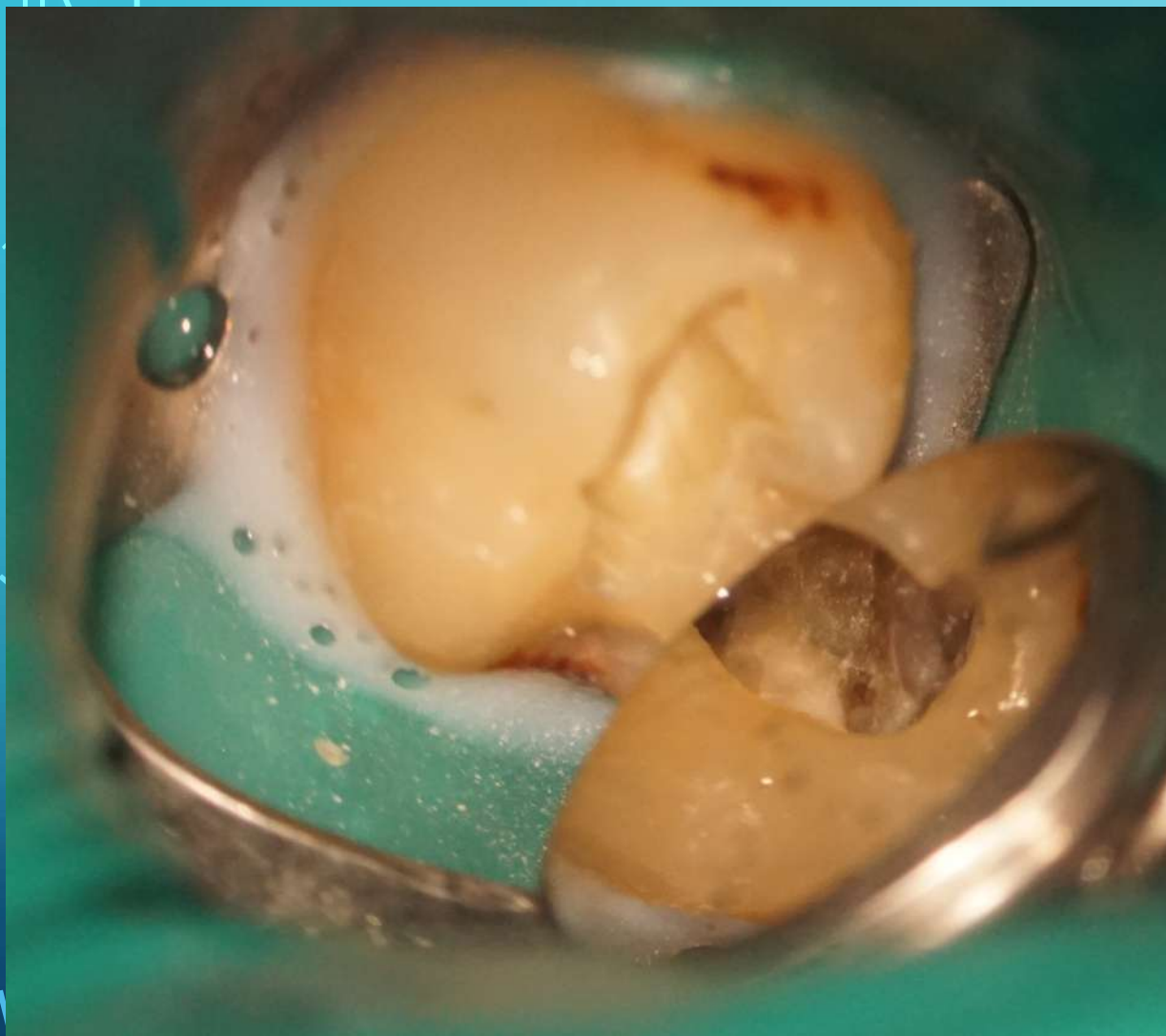


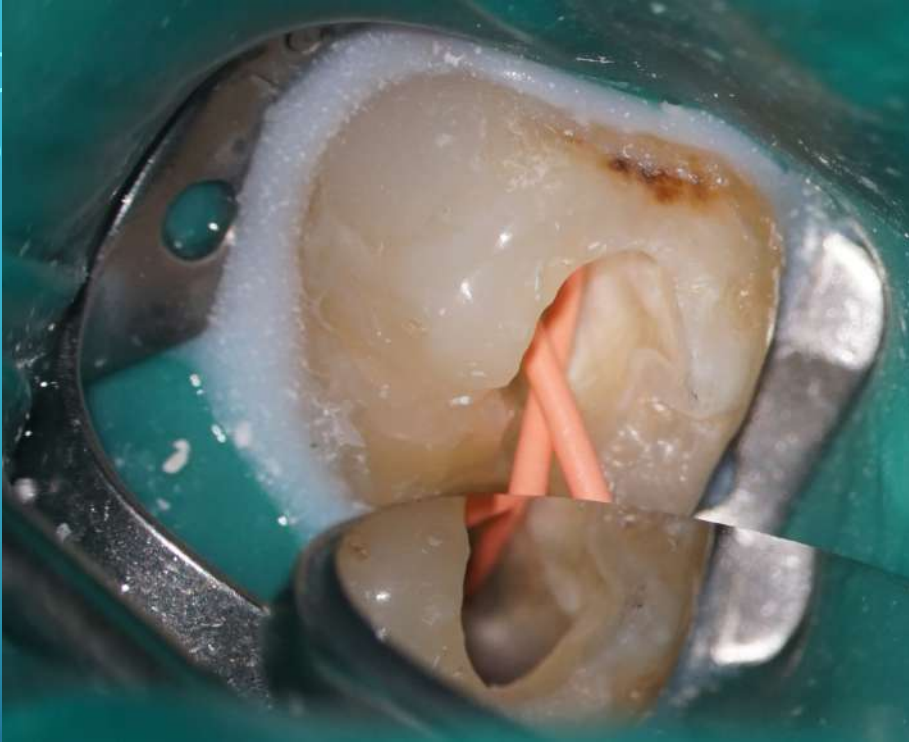CERVICAL RESORPTION

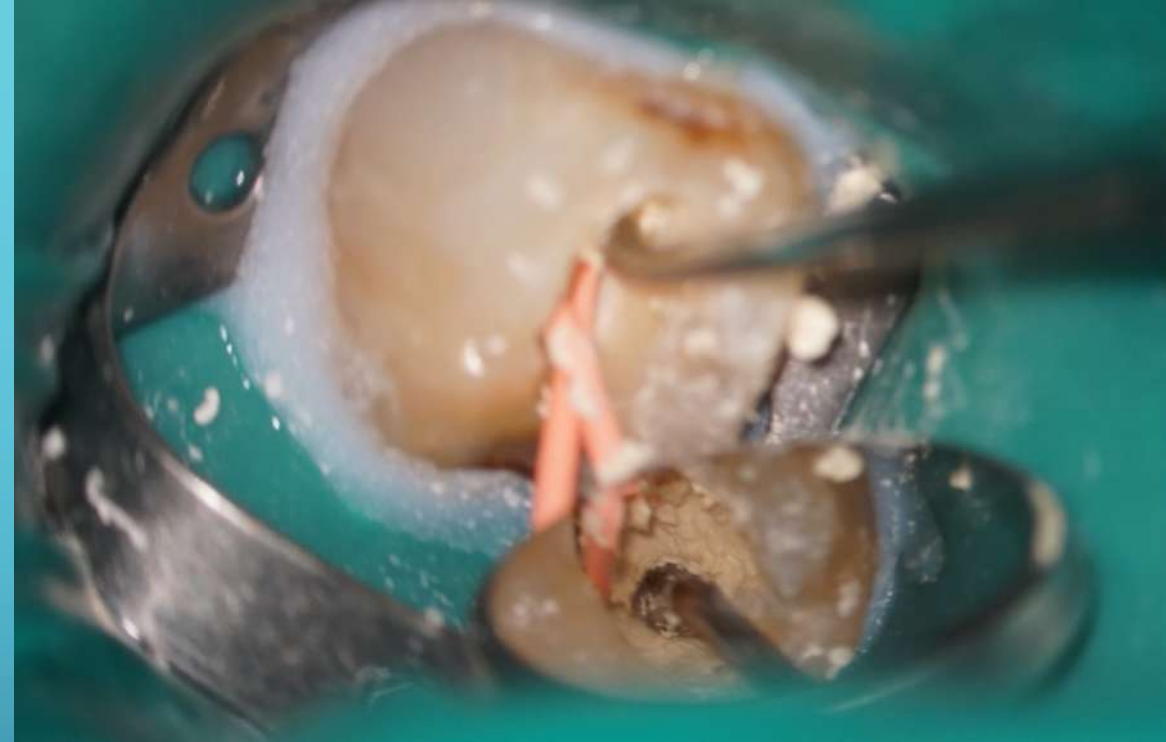NEXT APPOINTMENT - PREPARATION OF DENTINAL RESORPTION AND PULP CHAMBE.



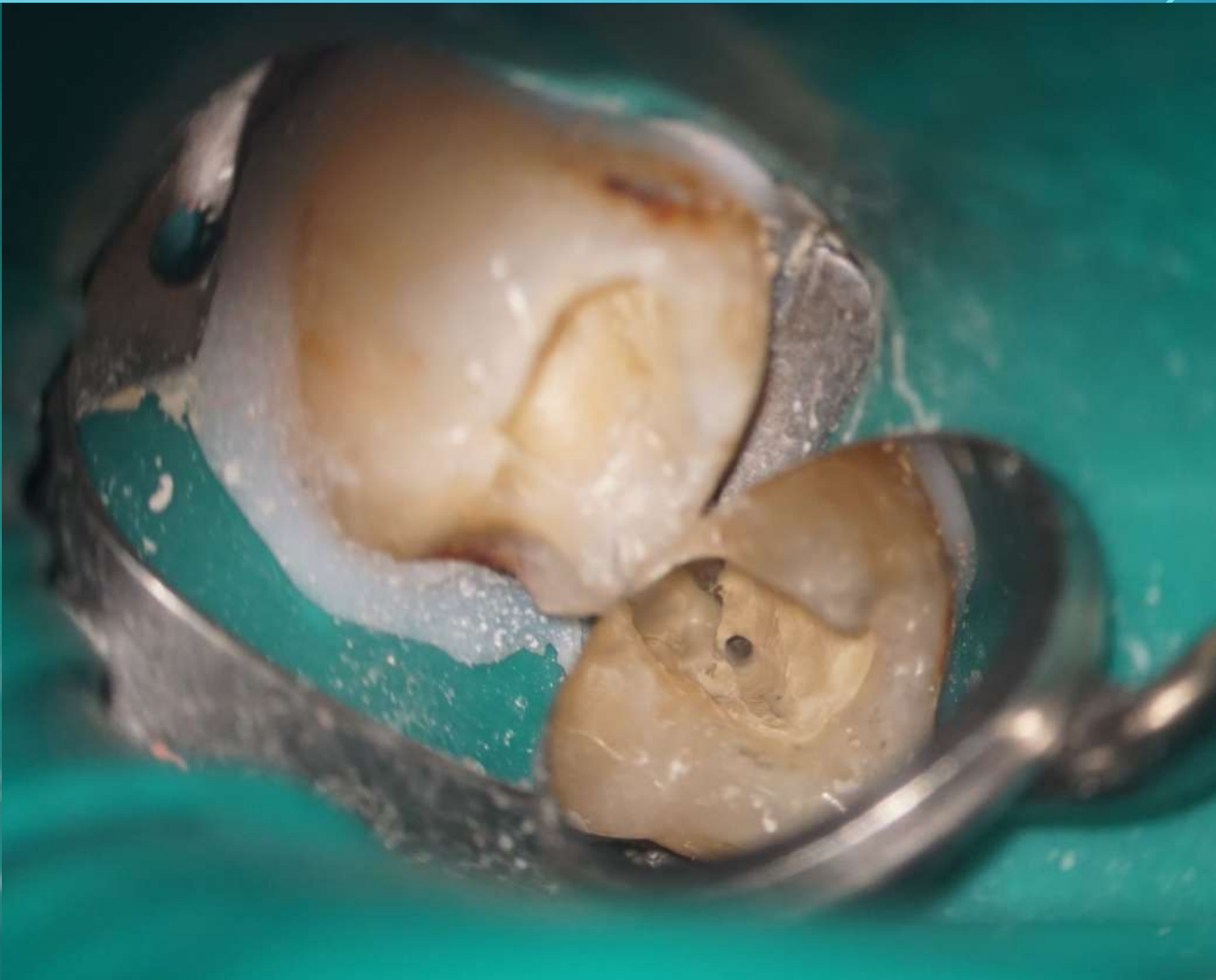
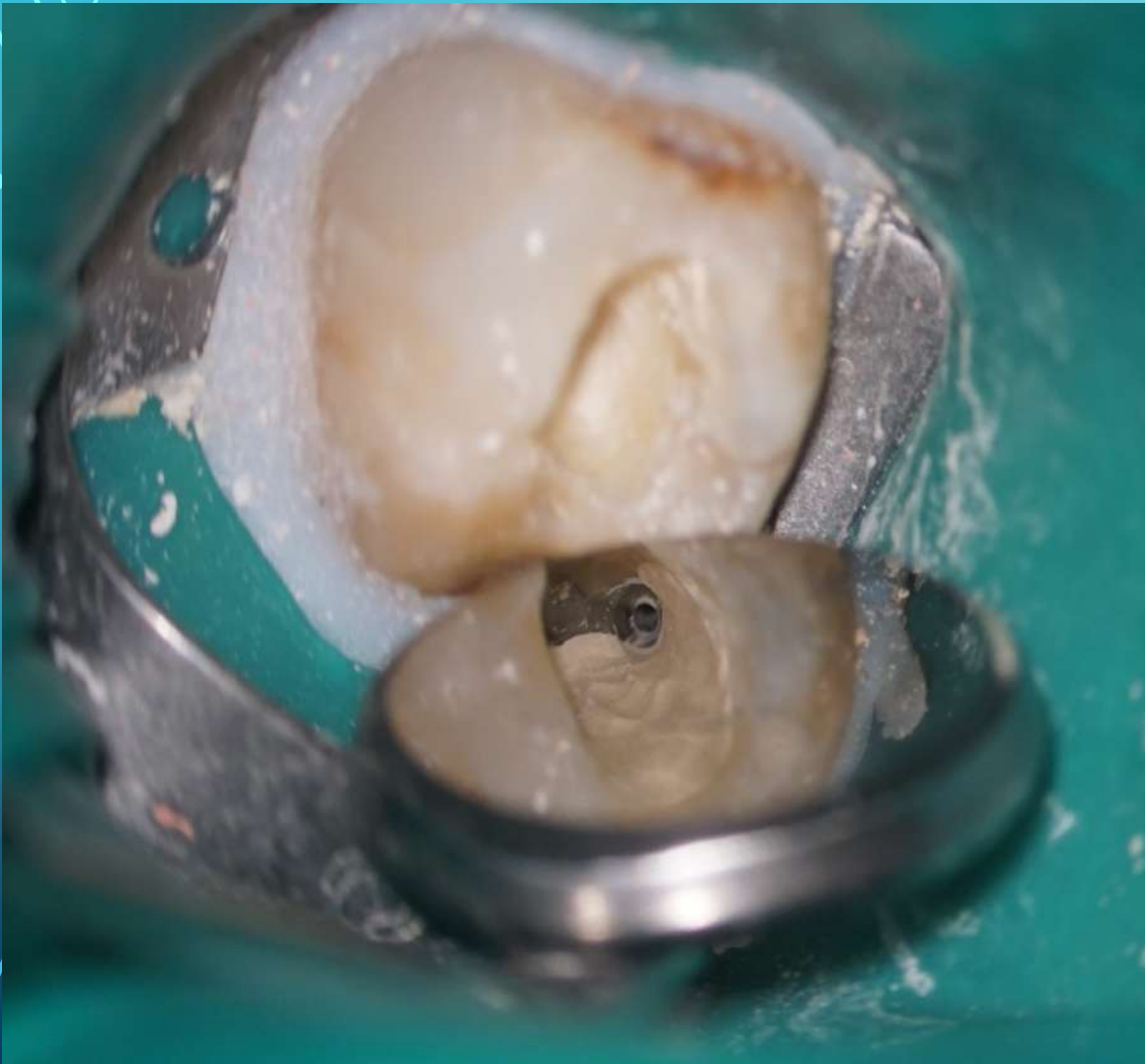


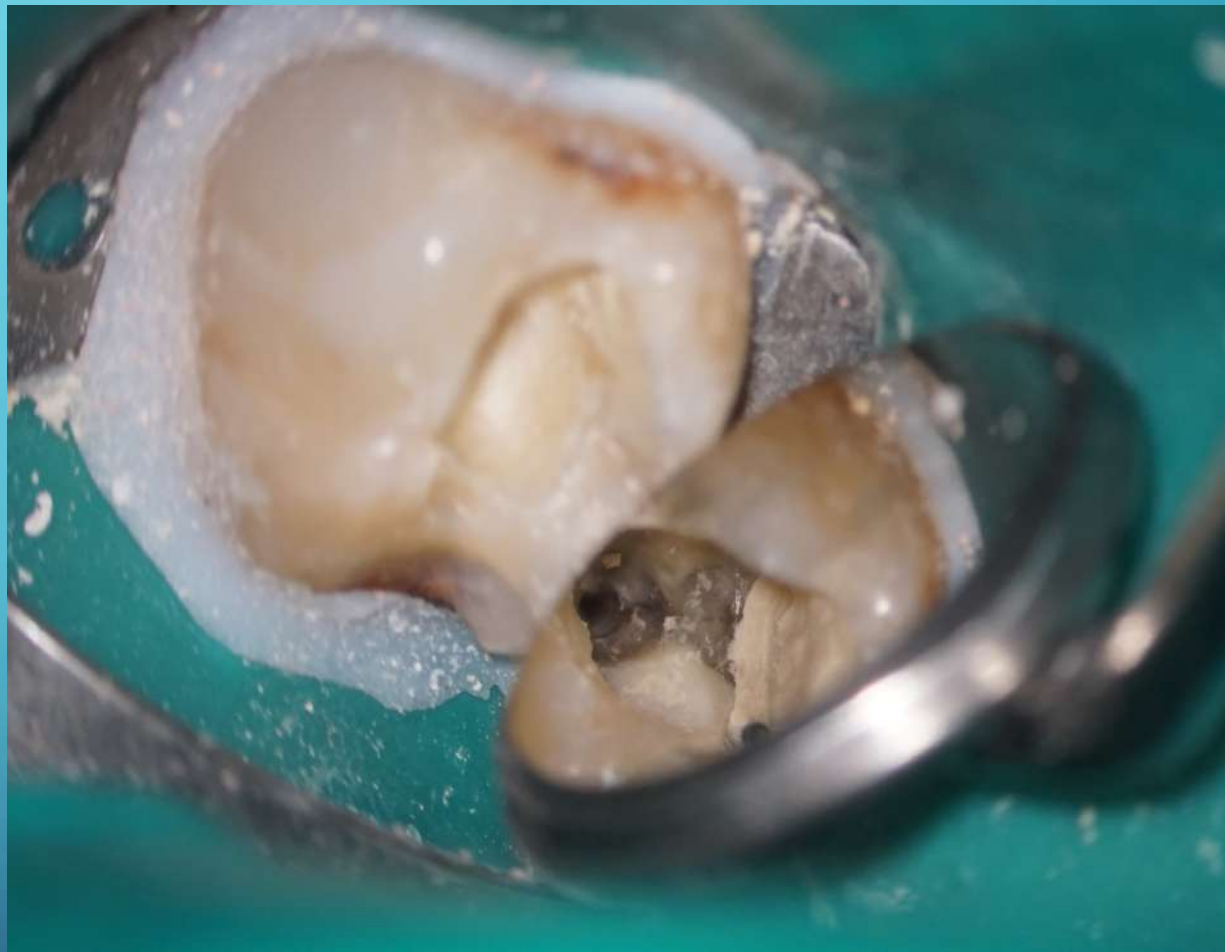
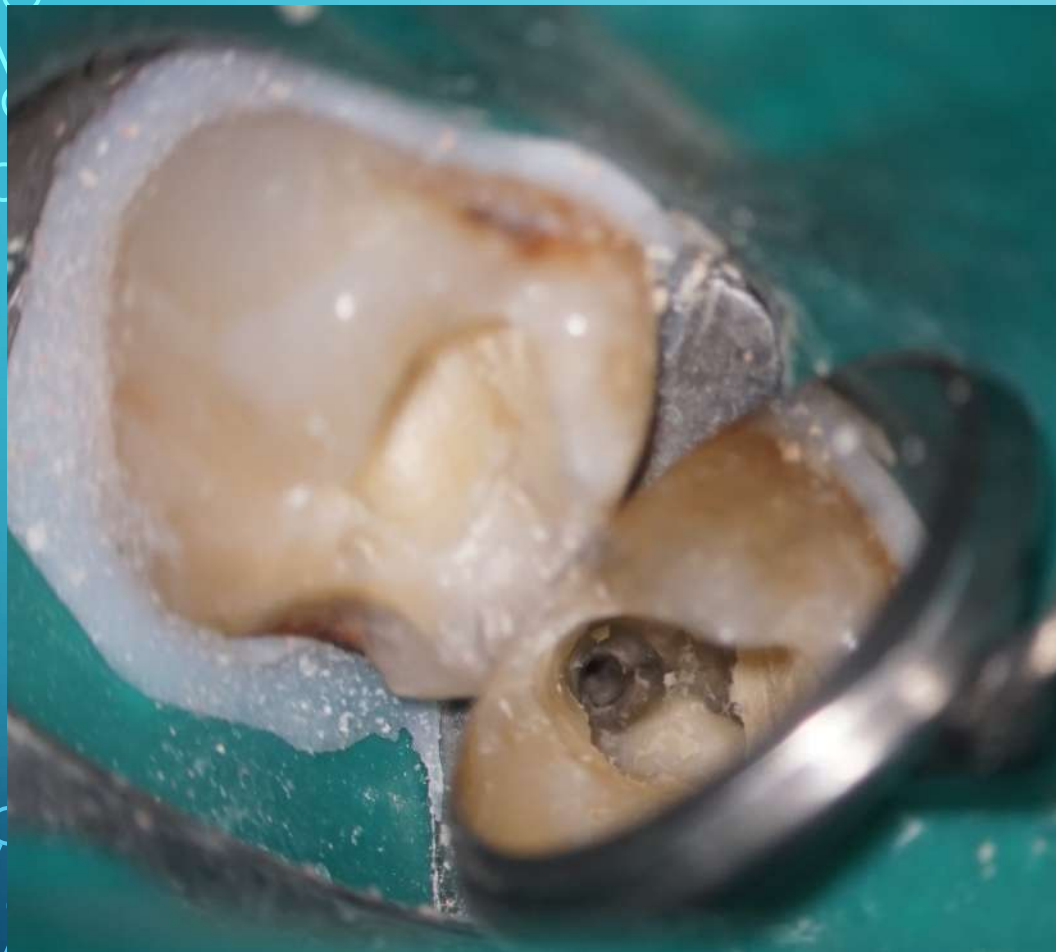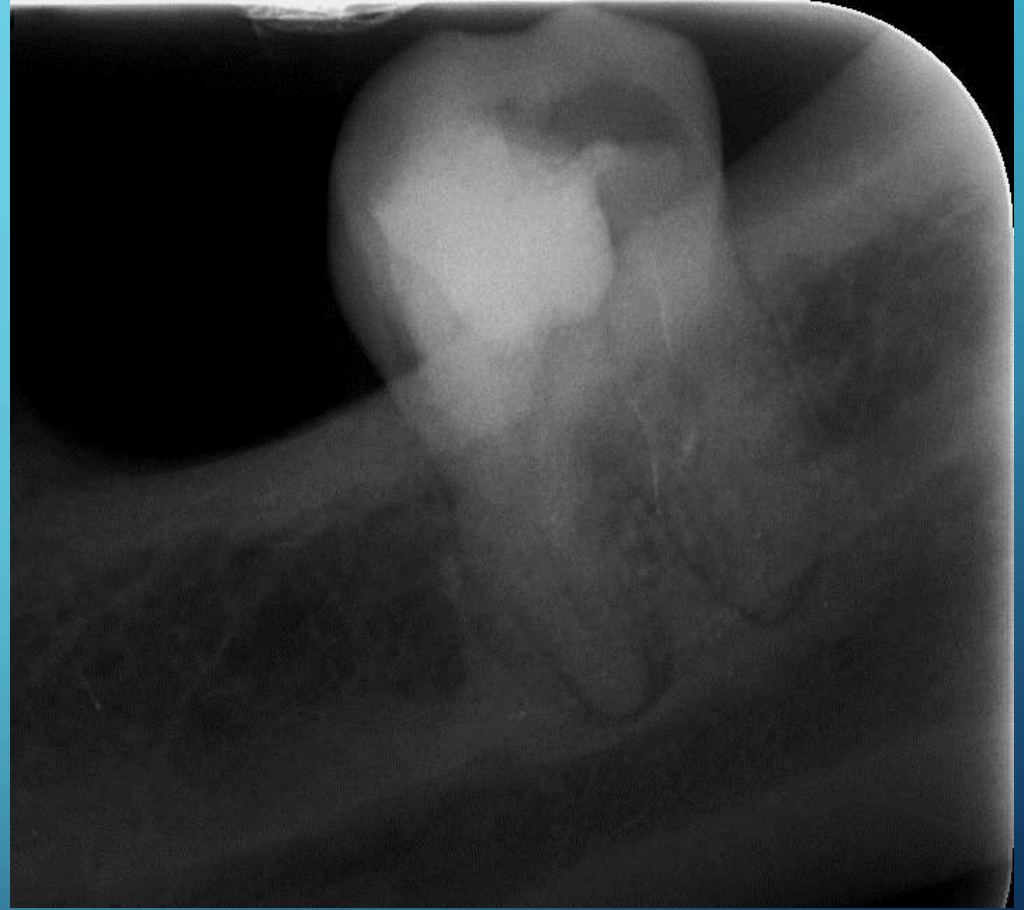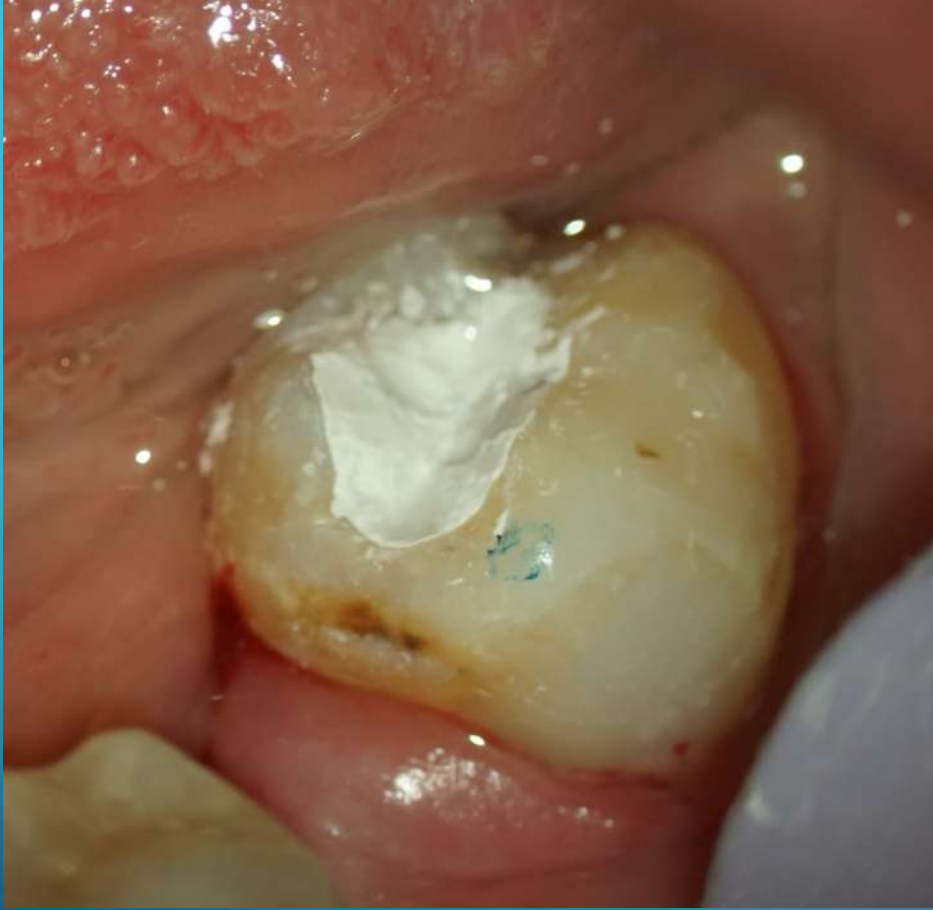Protection of orifice mesial canals by gutta percha points



Filling resorption defect by bioceramic material
–Biodentine (Septodont)







DDS Jacek Bilbin