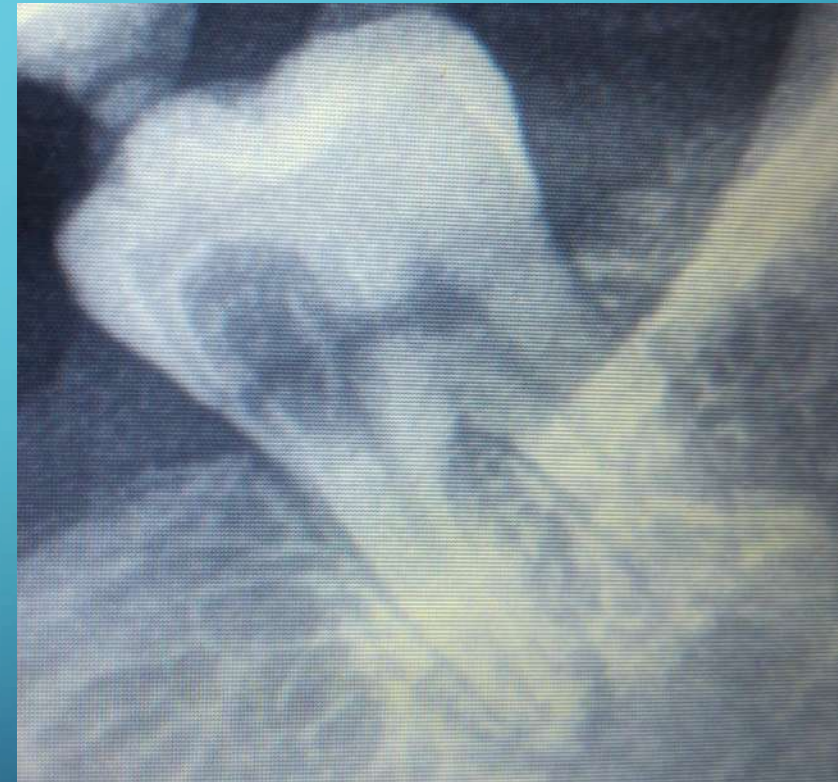
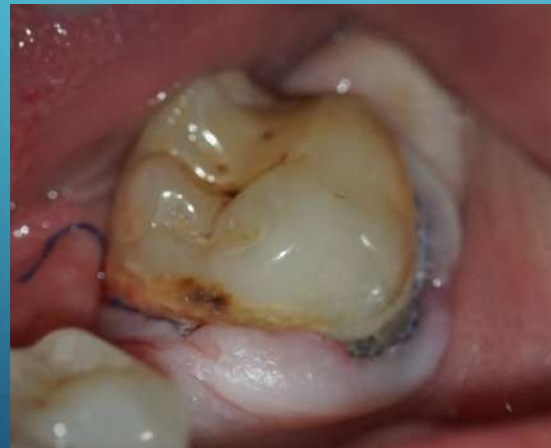
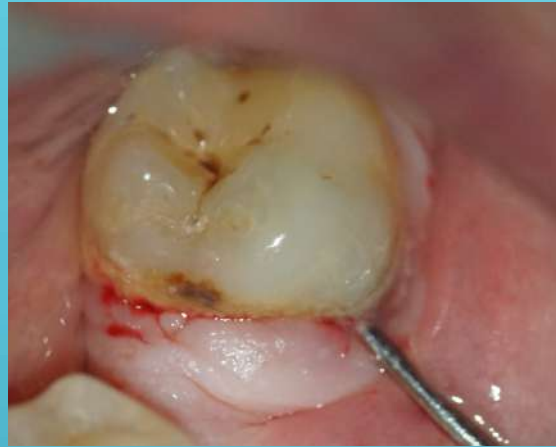
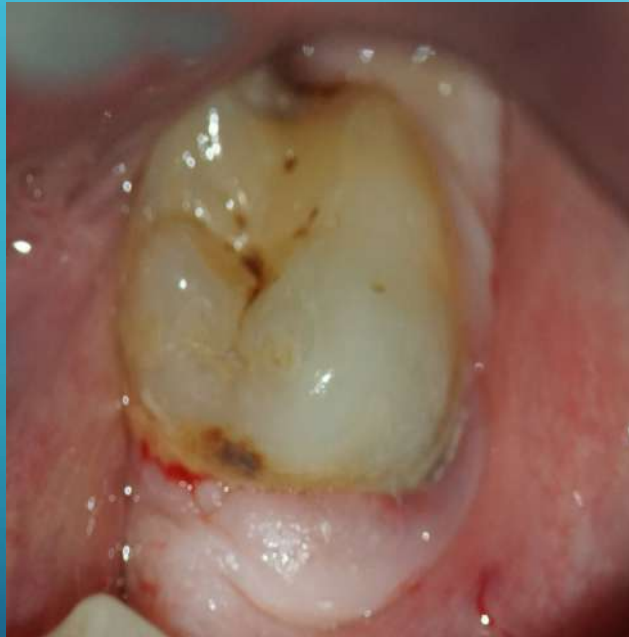
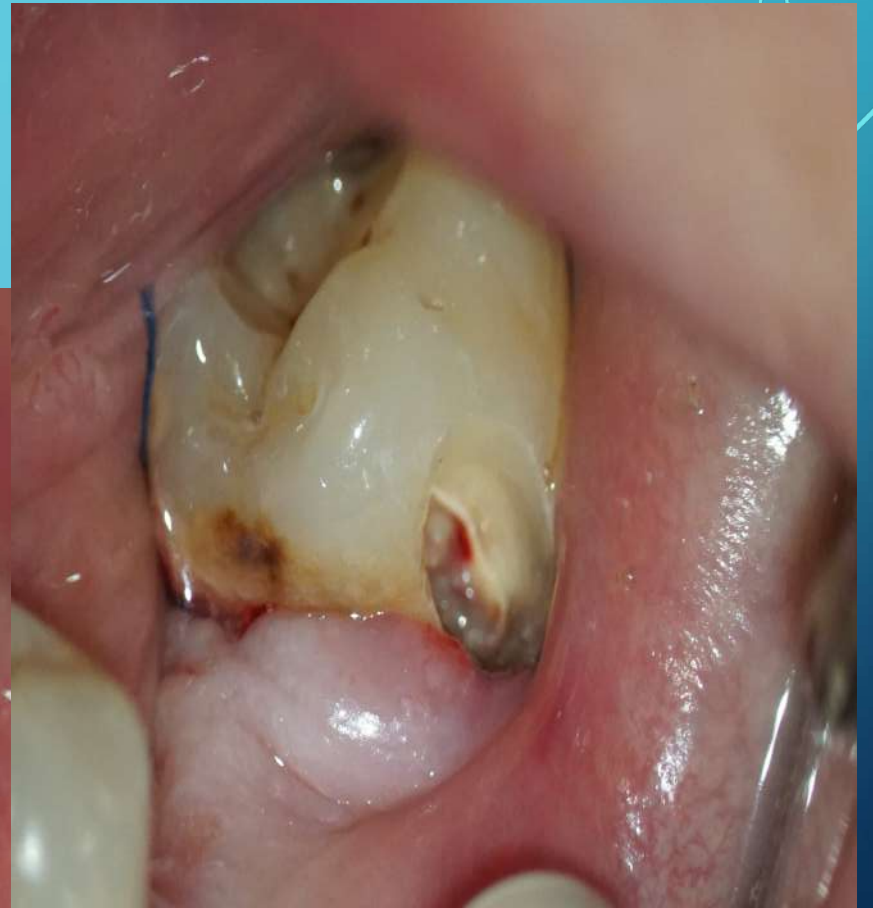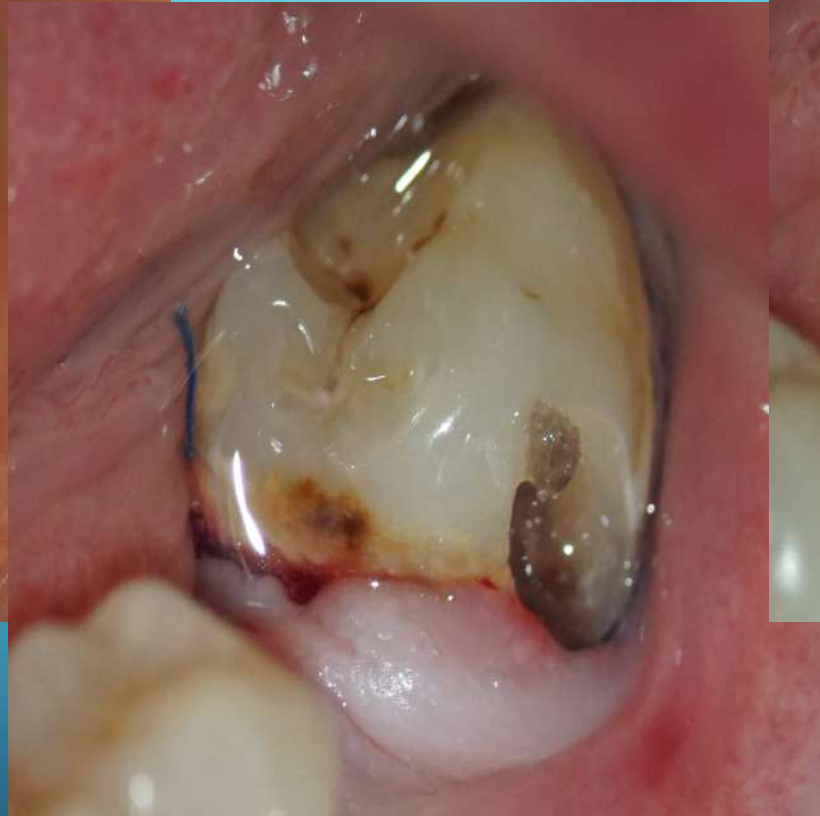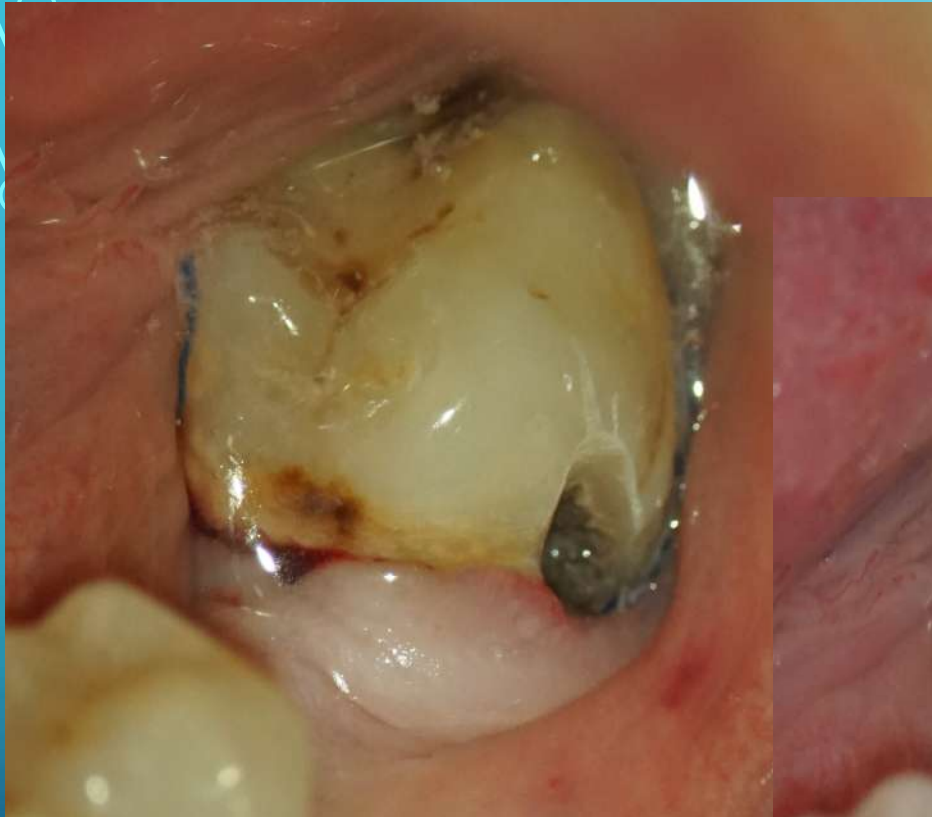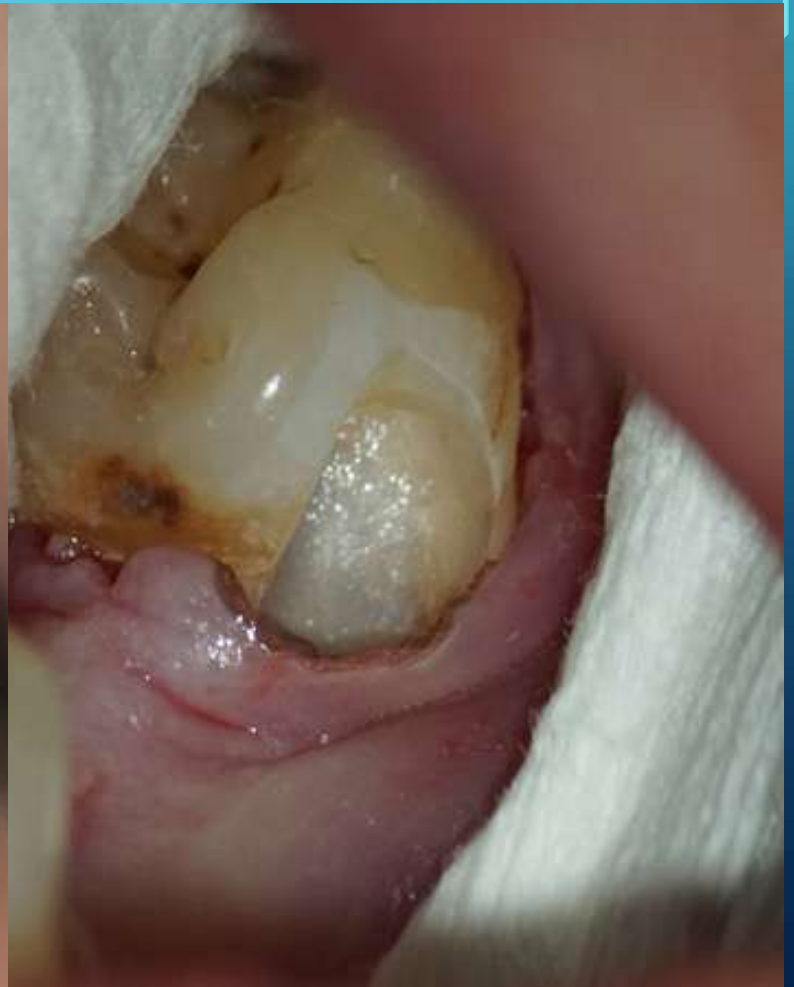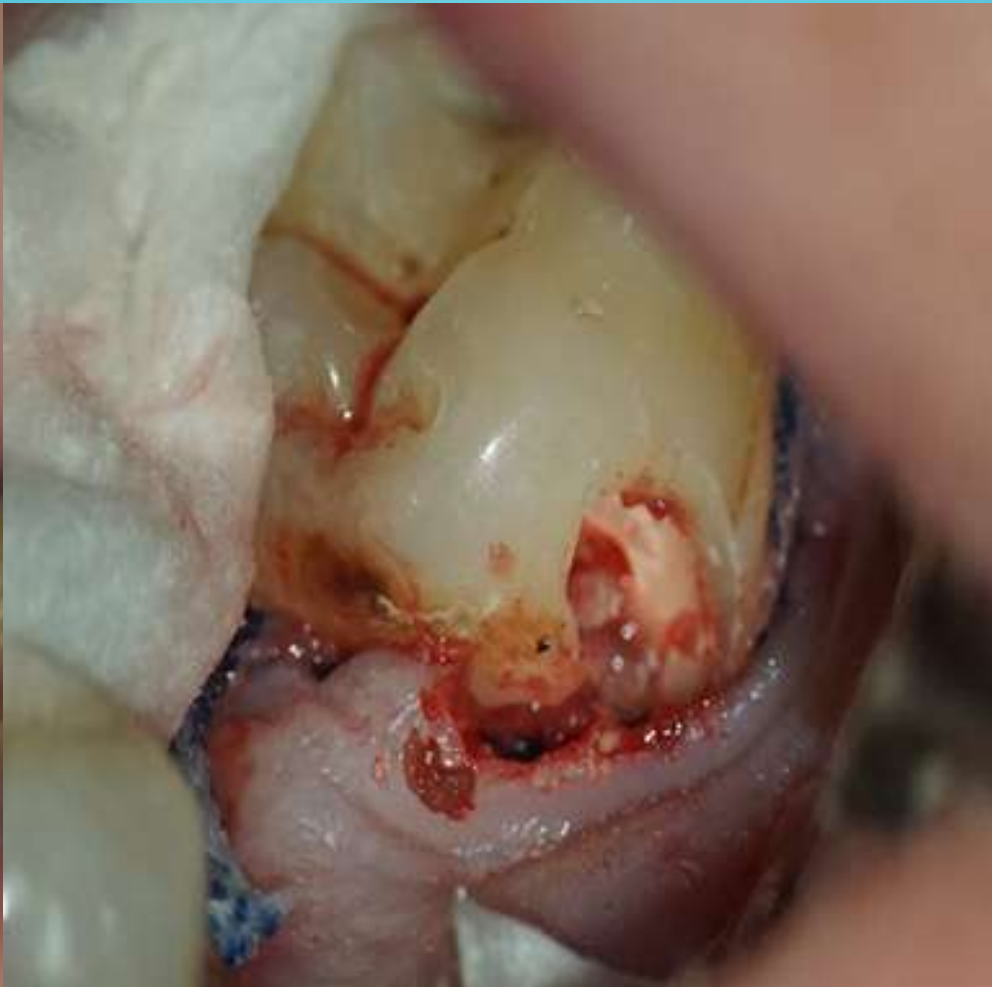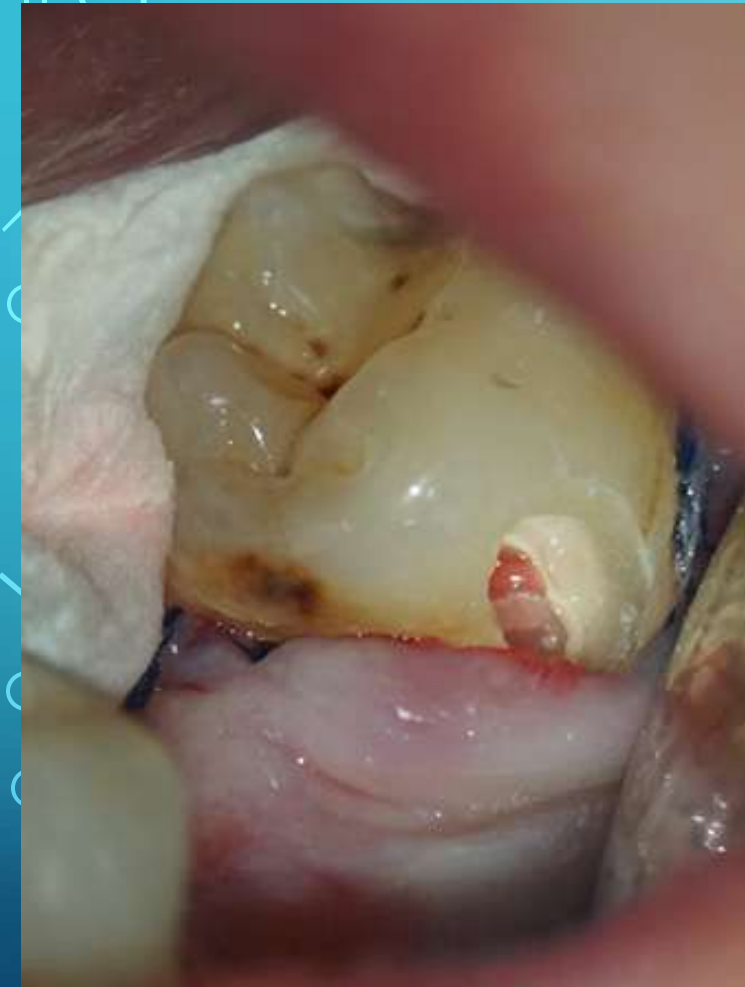# INVASIVE CERVICAL RESORPTION

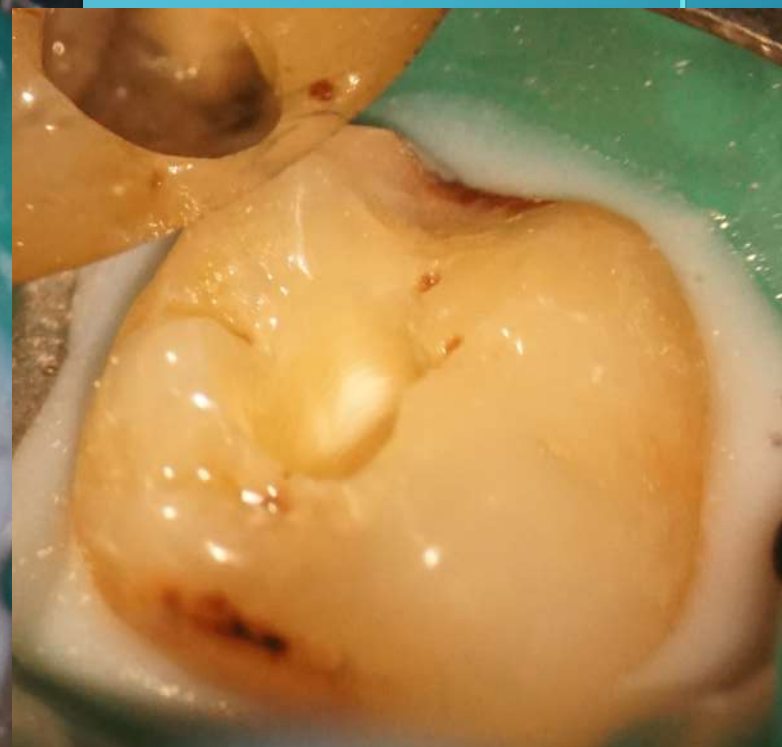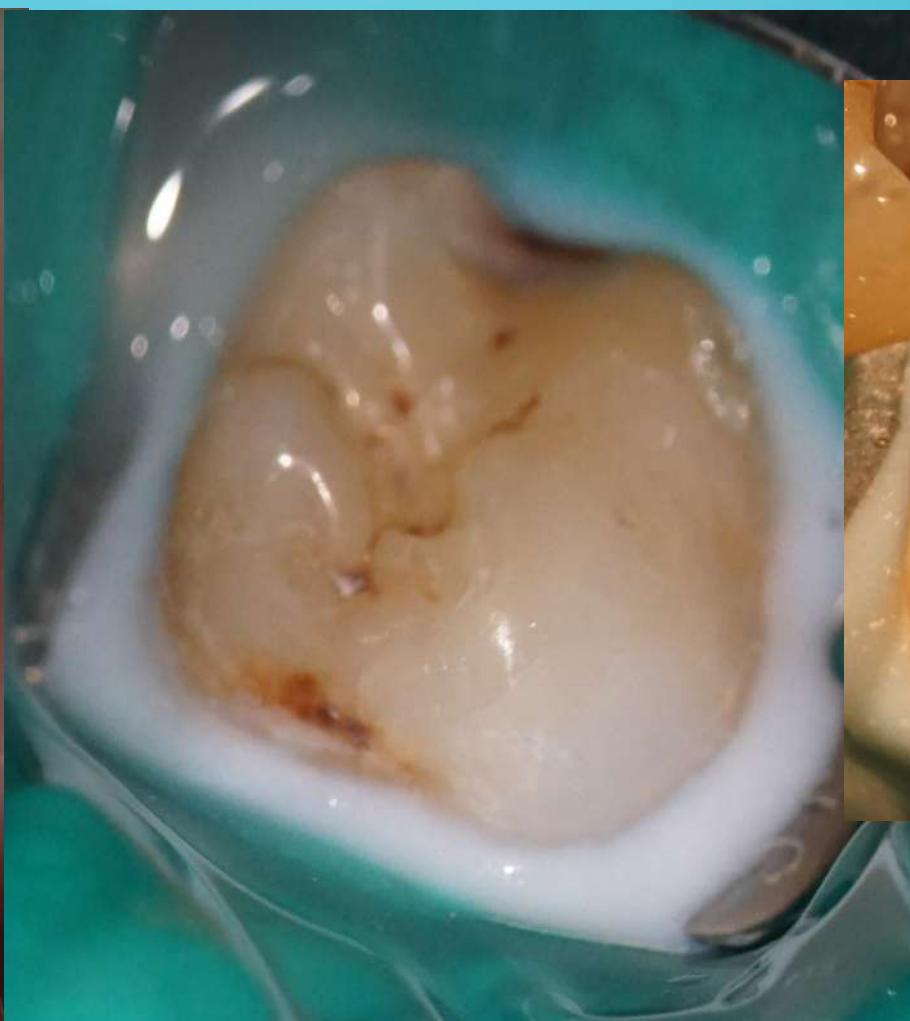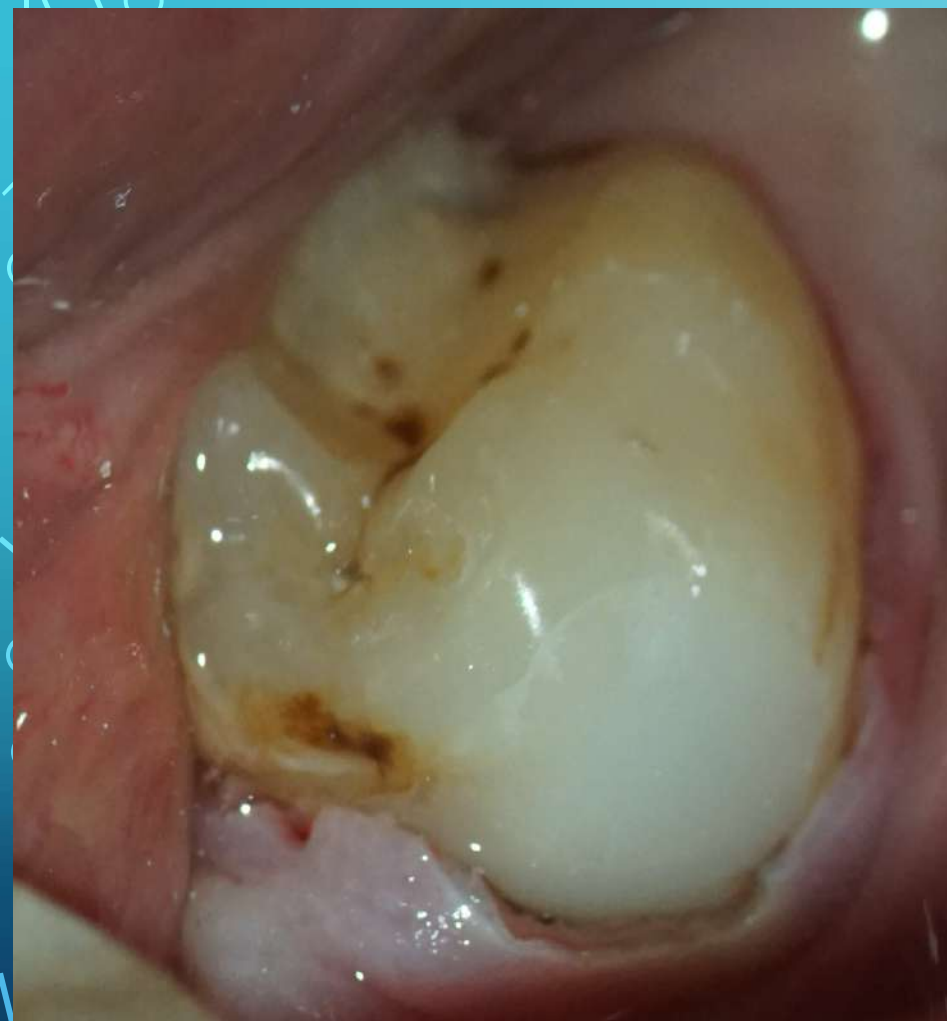
DDS JACEK BILBIN

Women 45 years old has problem with tooth 37. Sometimes was spotaneous pain and bad smell . Tooth look intact , only color of MR was different. I found small hole in the mesial root , then i made RVG.





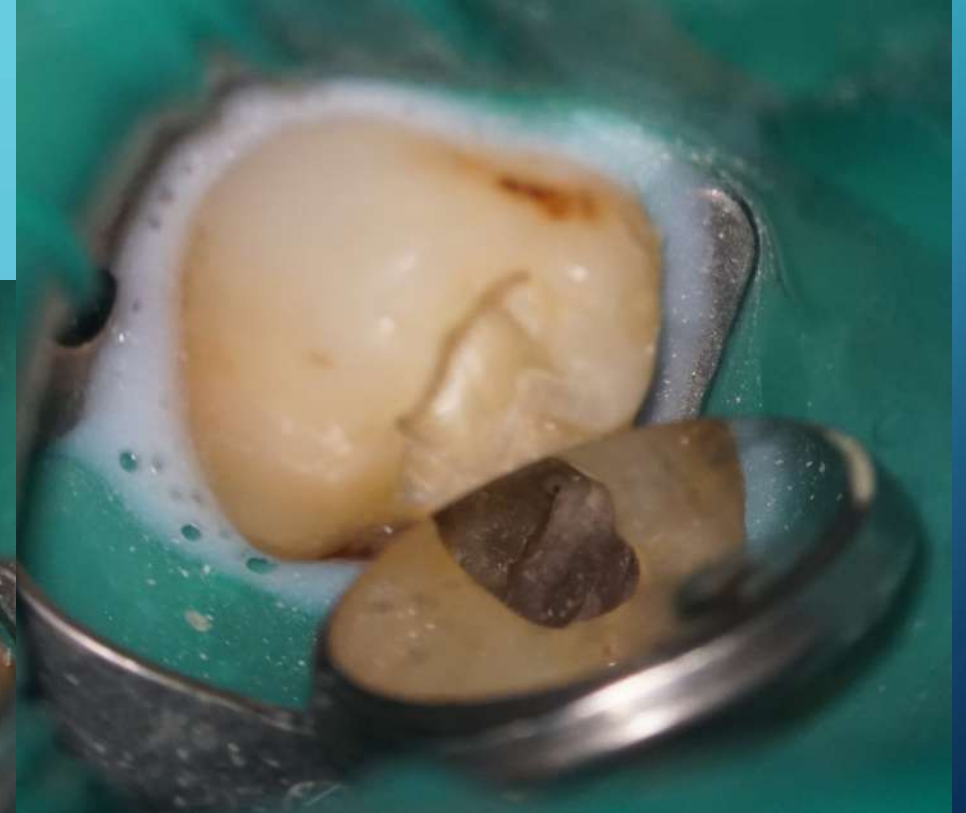
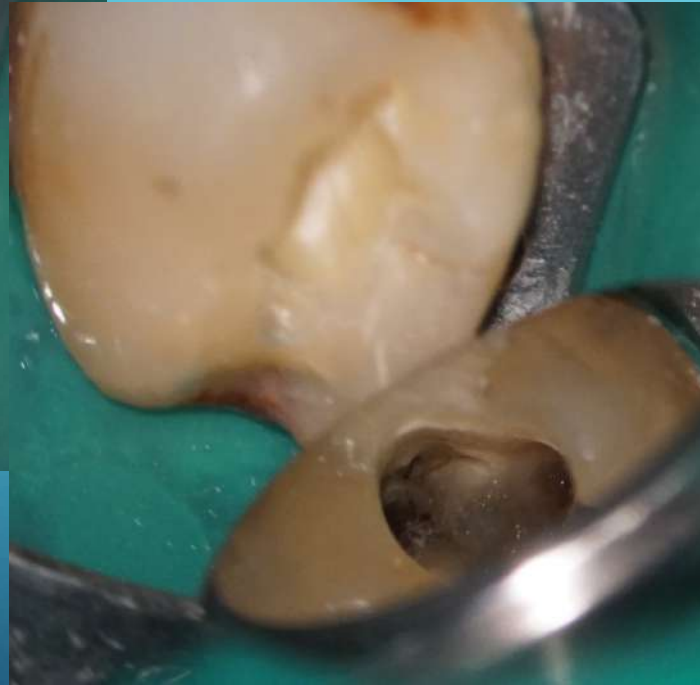
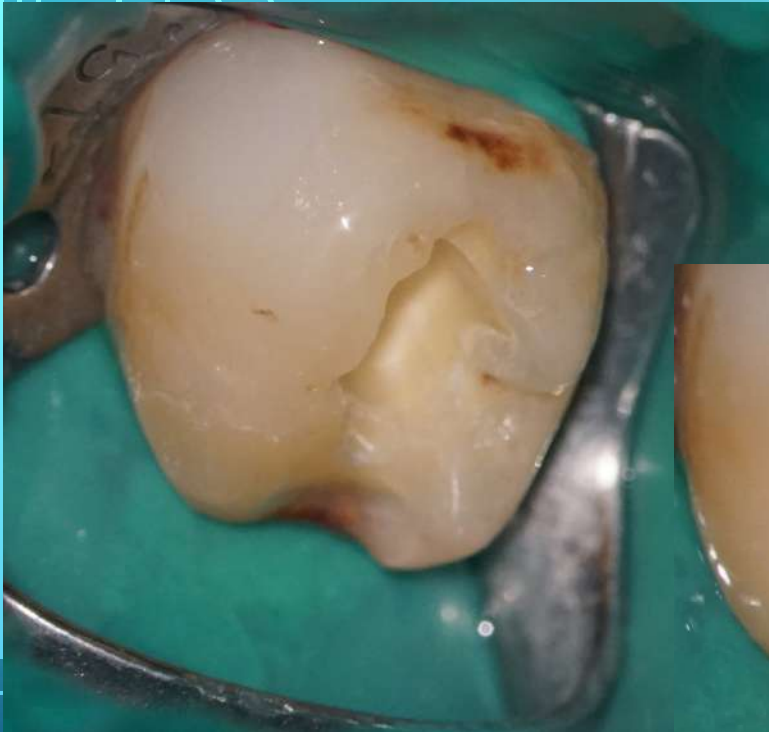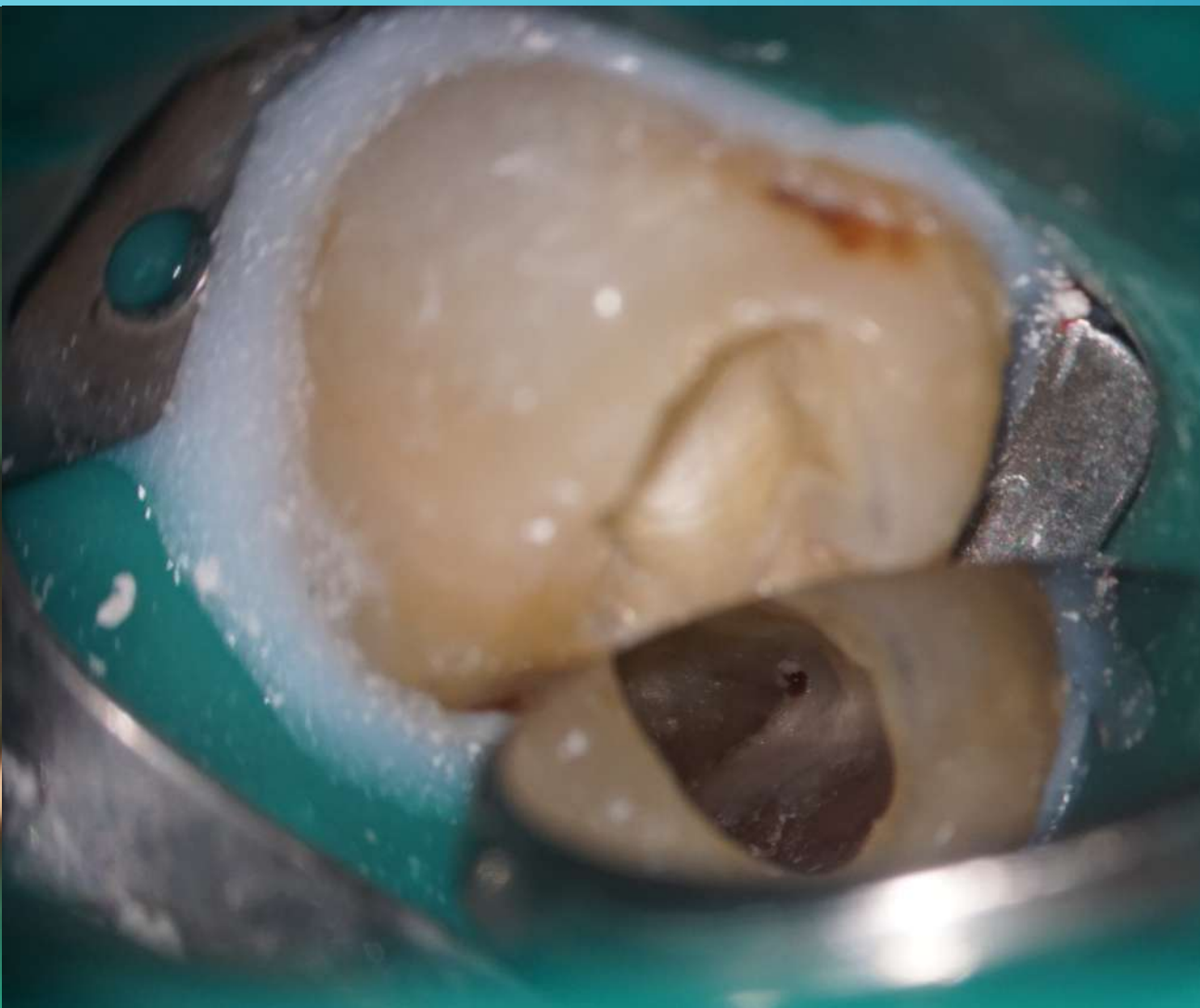
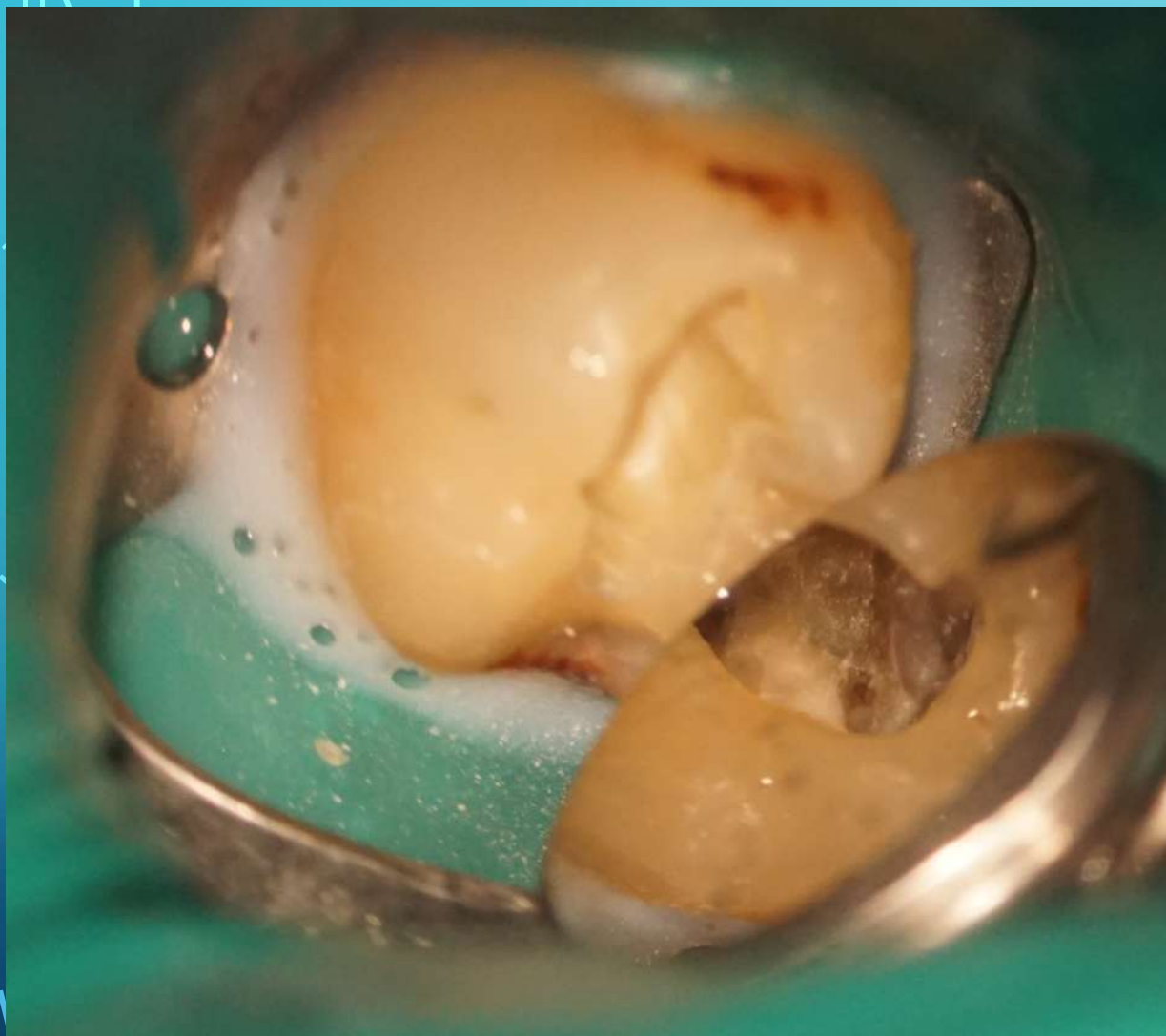


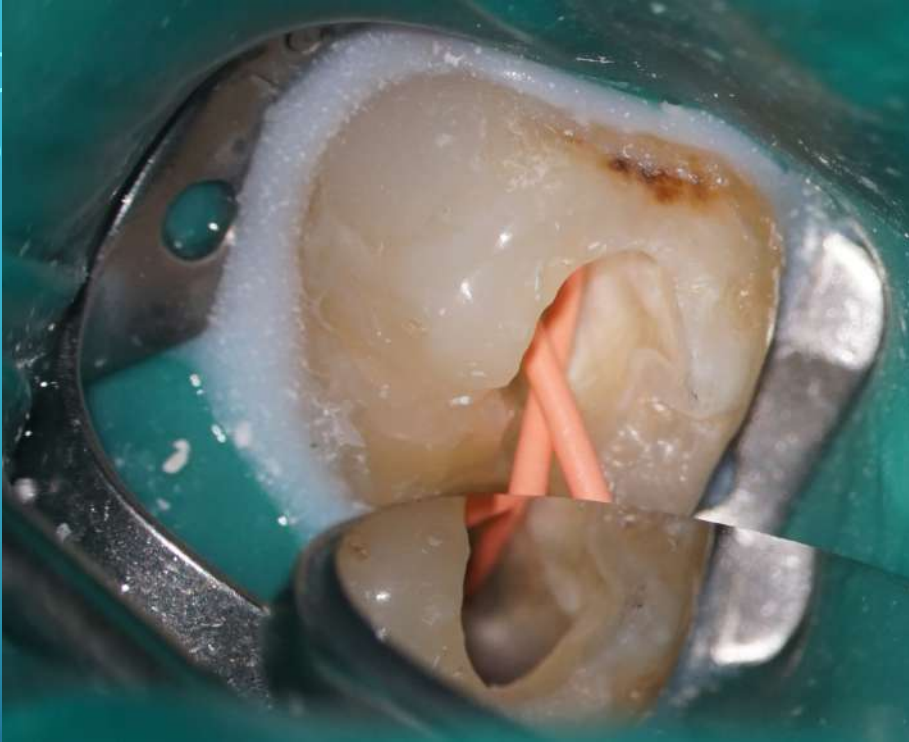DDS Jacek Bilbin

# CERVICAL RESORPTION

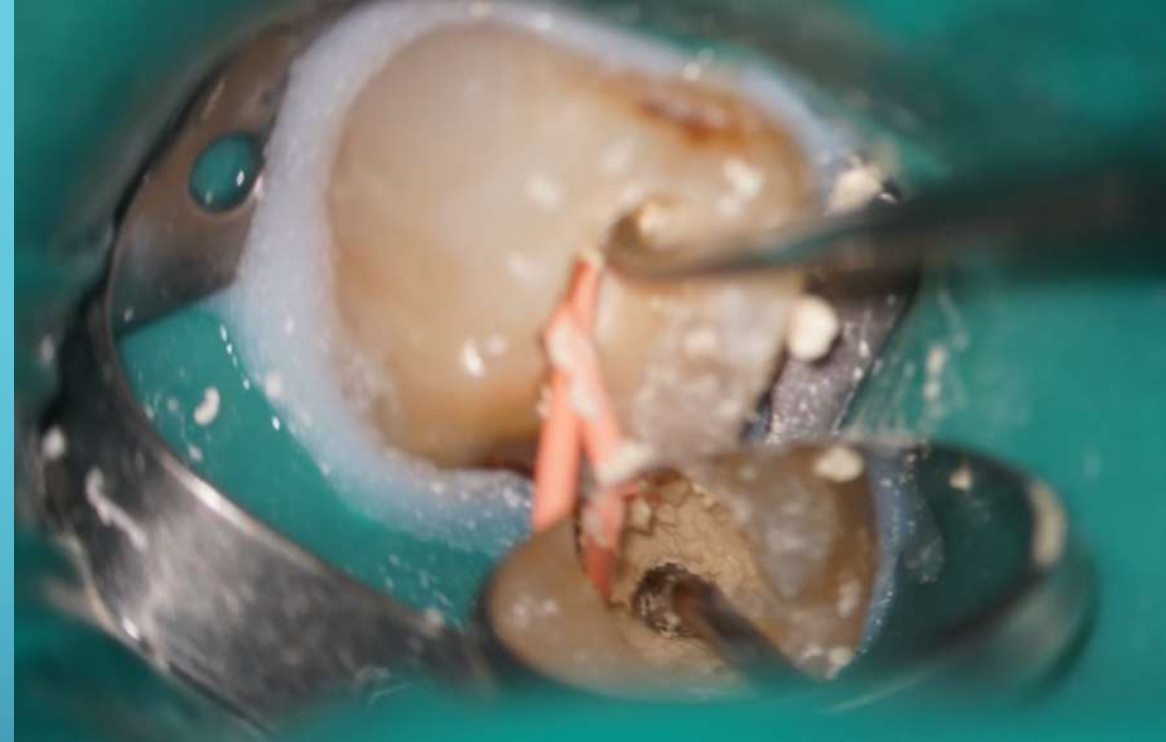NEXT APPOINTMENT - PREPARATION OF DENTINAL RESORPTION AND PULP CHAMBE.





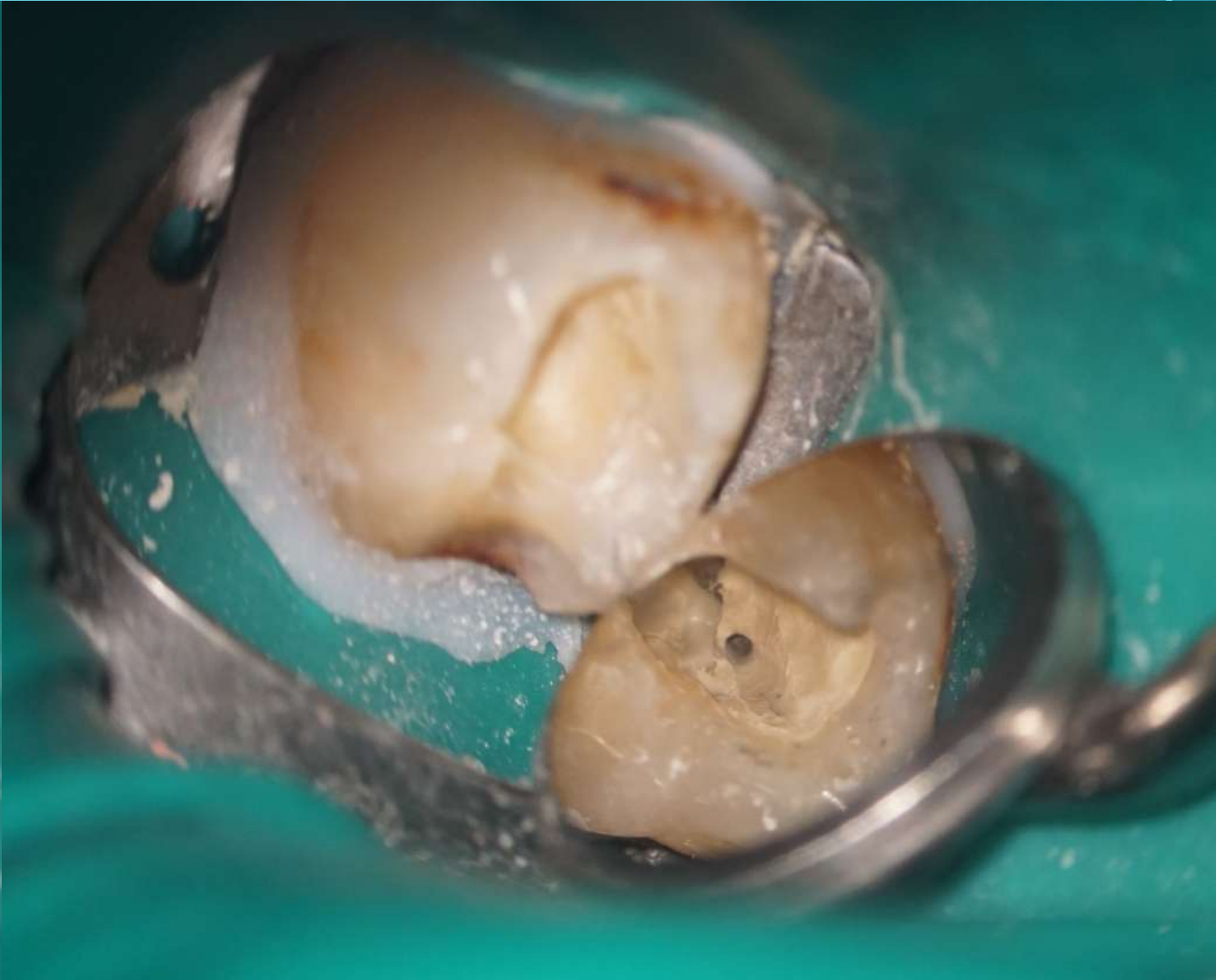
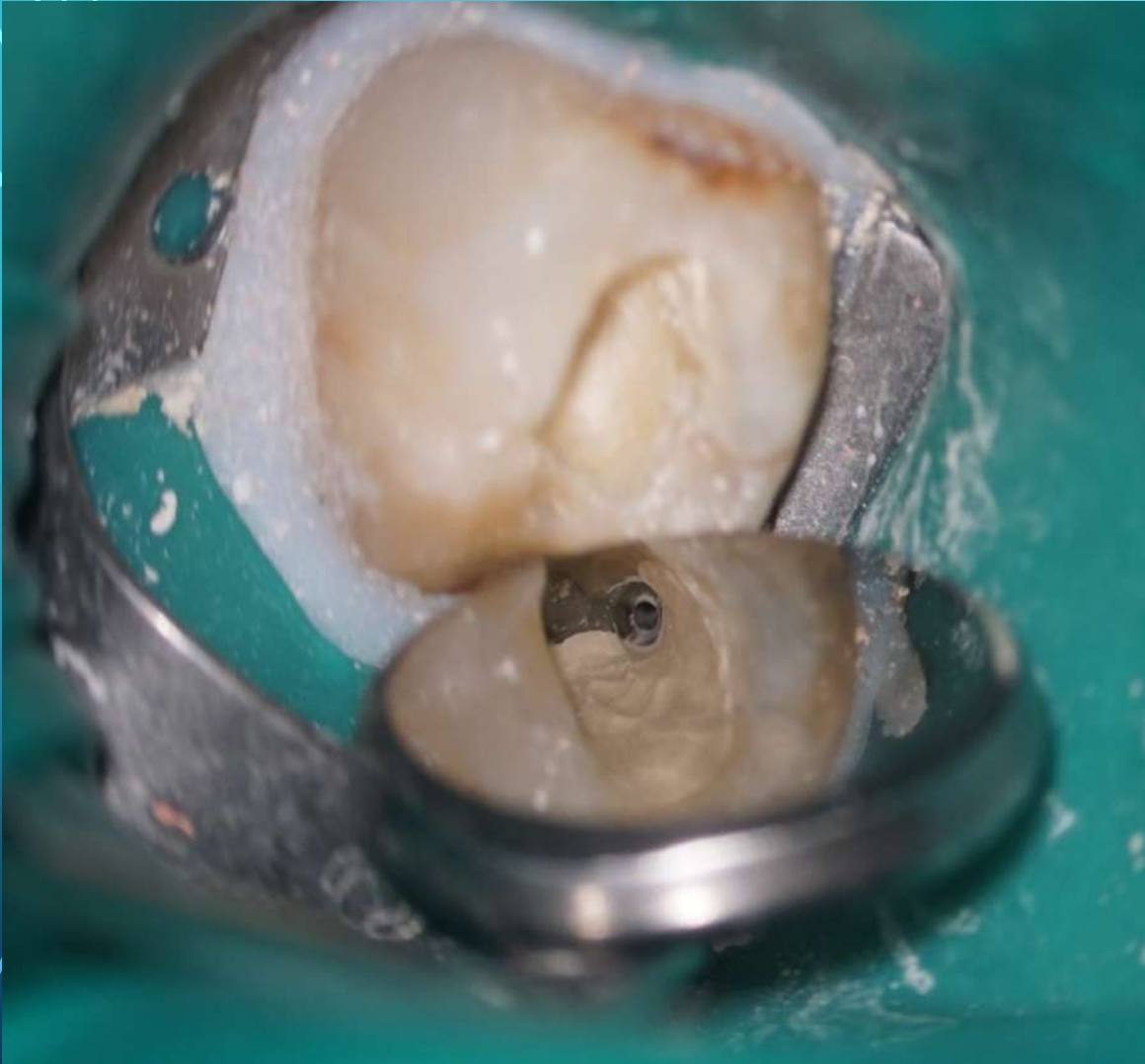
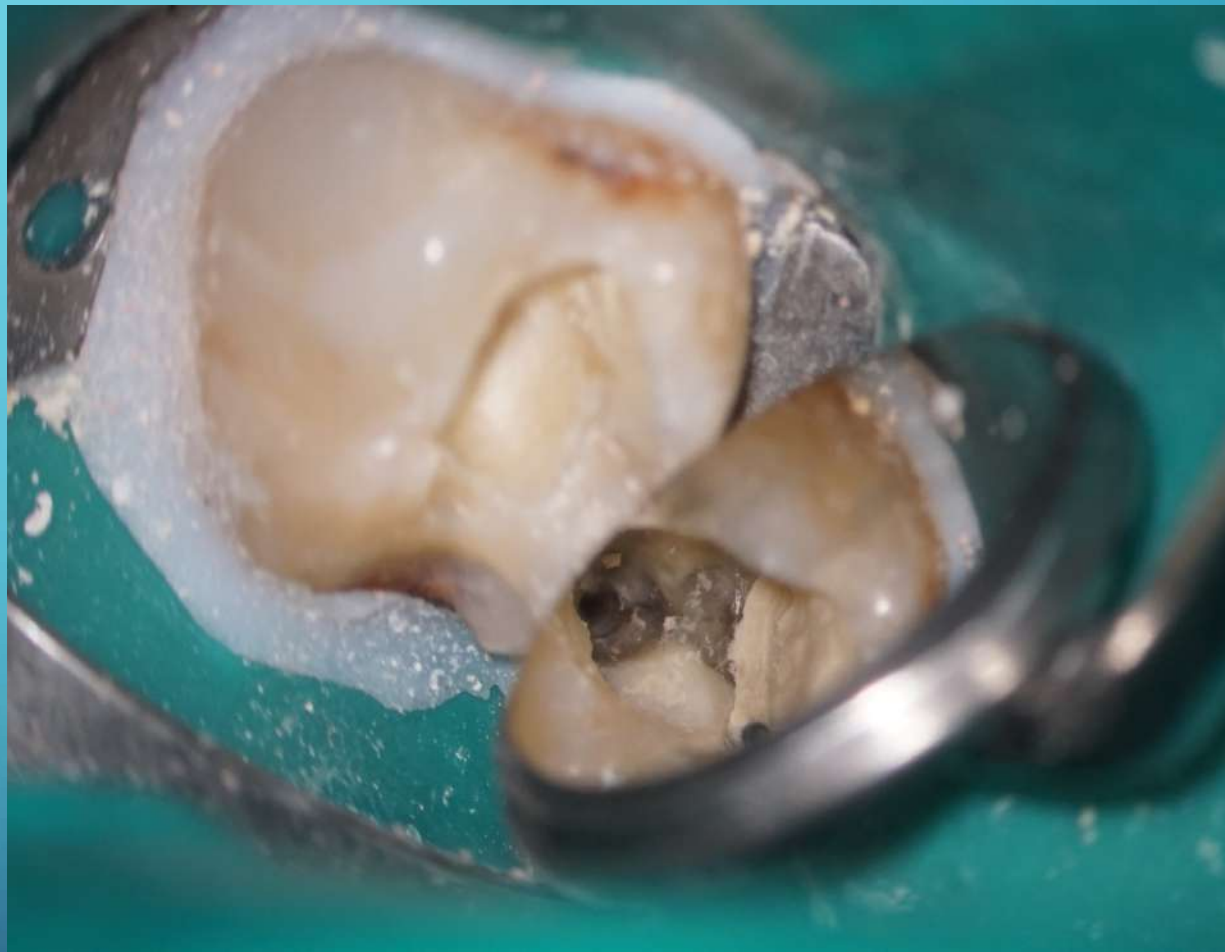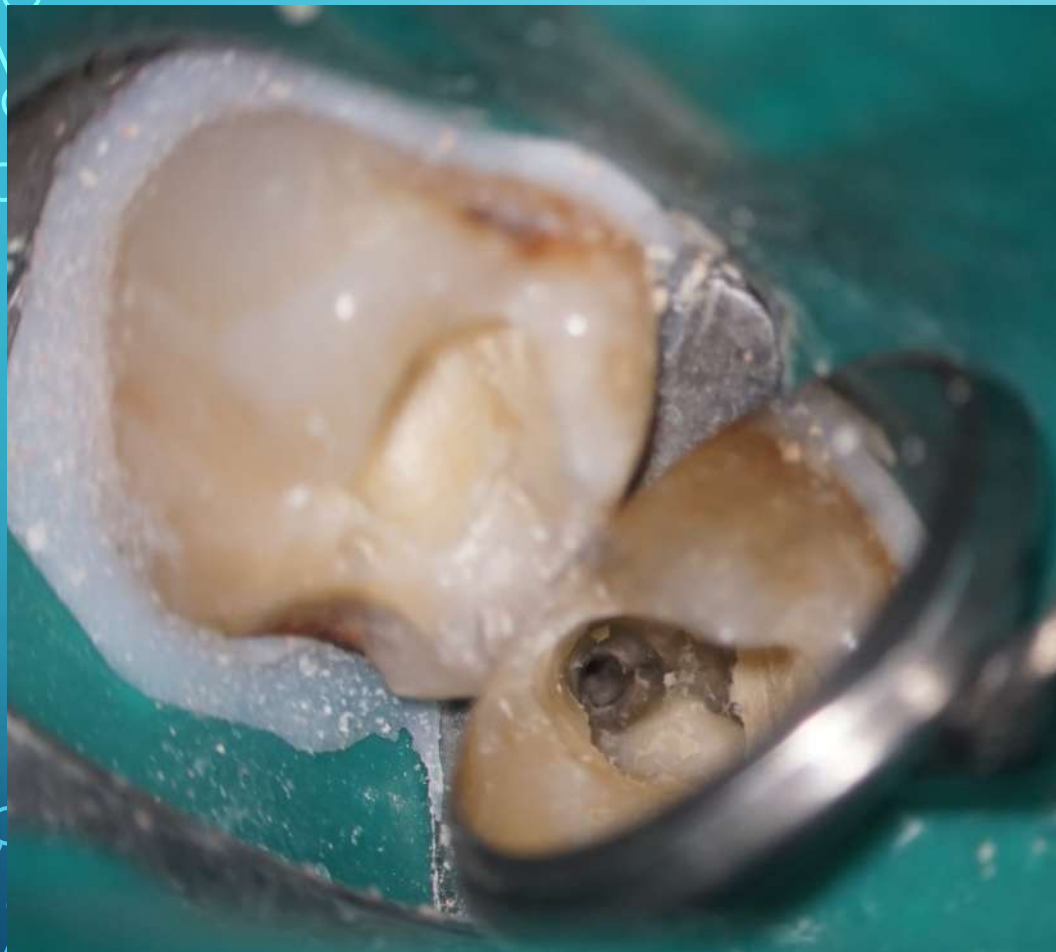Protection of orifice mesial canals by gutta percha points

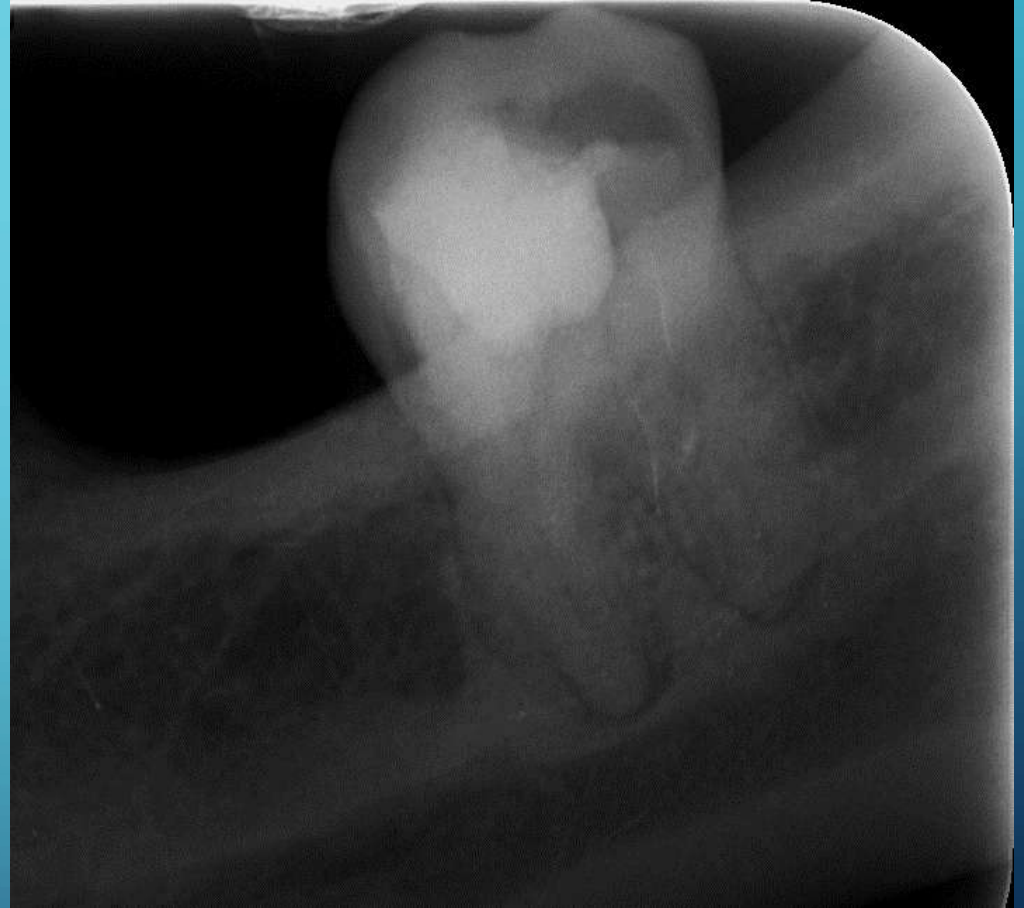
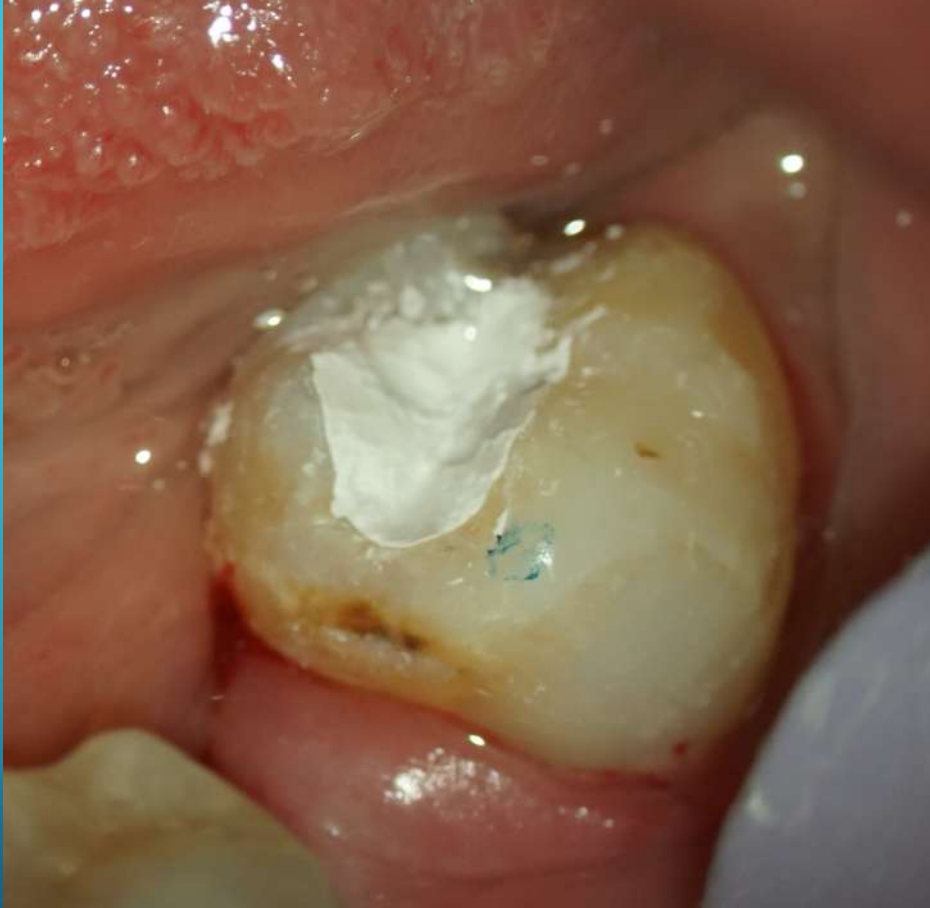
Filling resorption defect by bioceramic material –Biodentine ( Septodont)

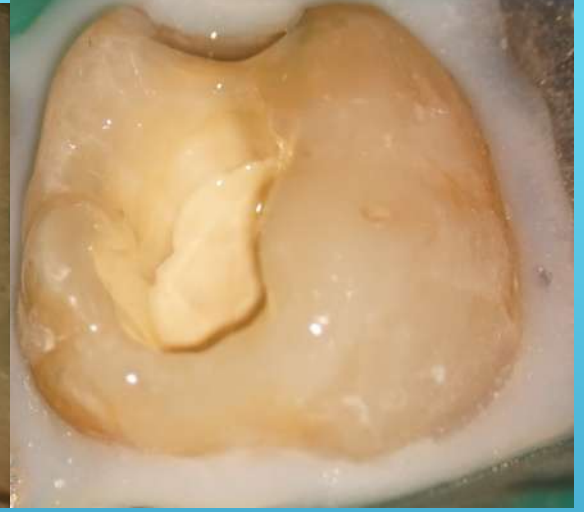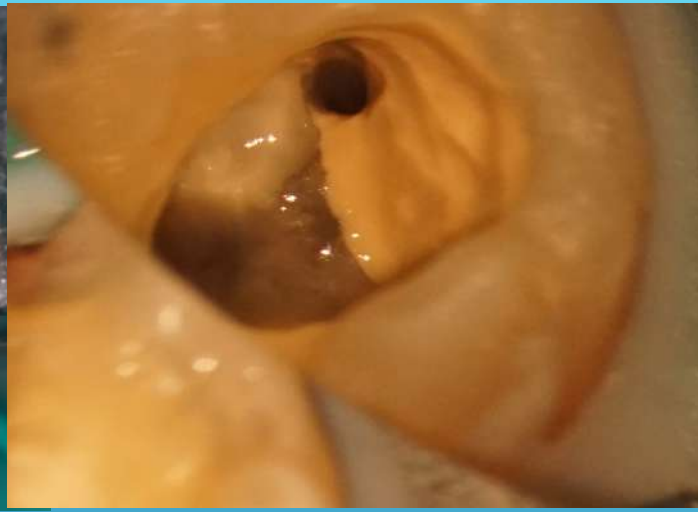

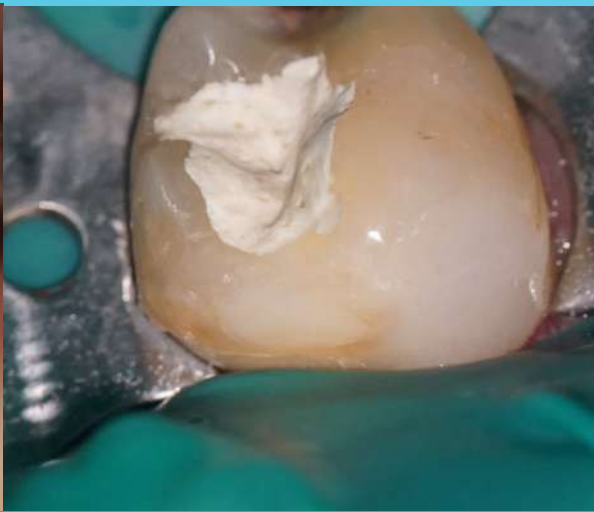
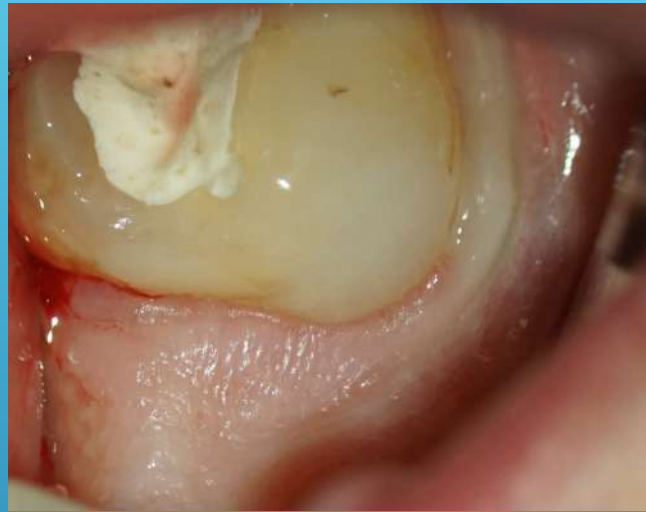




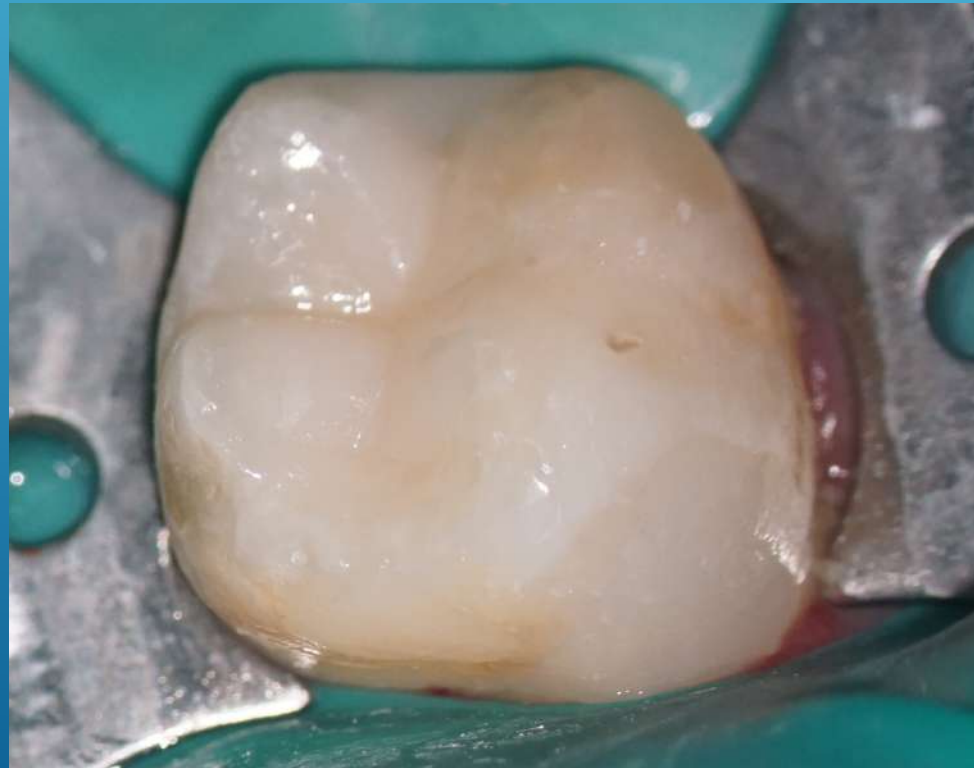
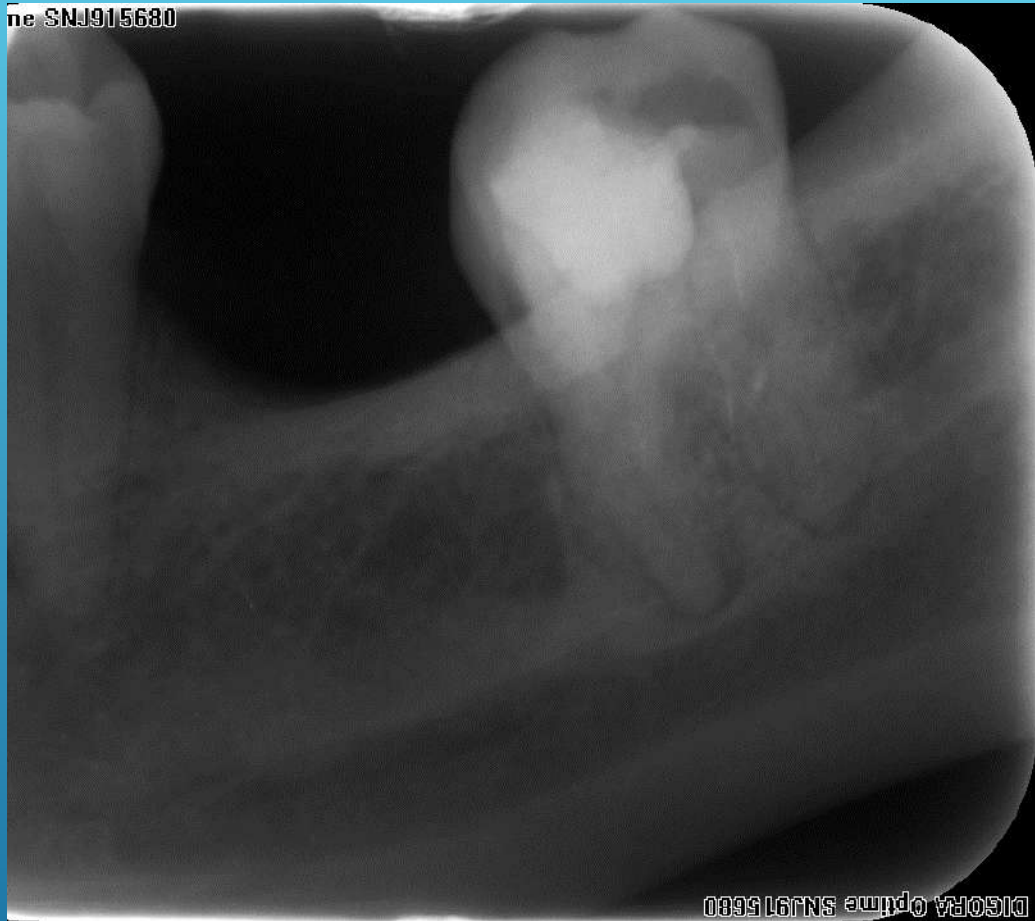DDS Jacek Bilbin

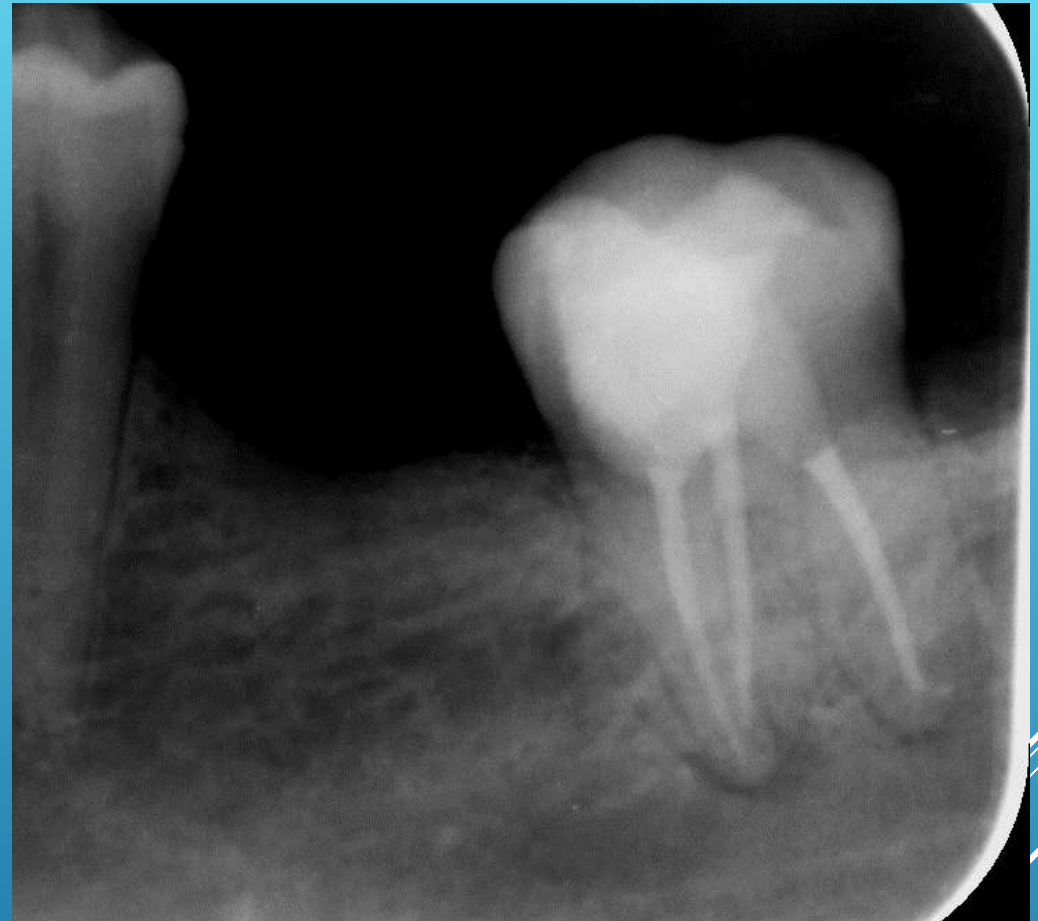

Root canal treatment. WL  
20mm, MB ML -RT file 35,  
Neonite , D RT 45 , B- System,  
Obtura , TotalFill. Buid-up-  
Biodentine (Septodonte),  
Eslelite OA1. ,

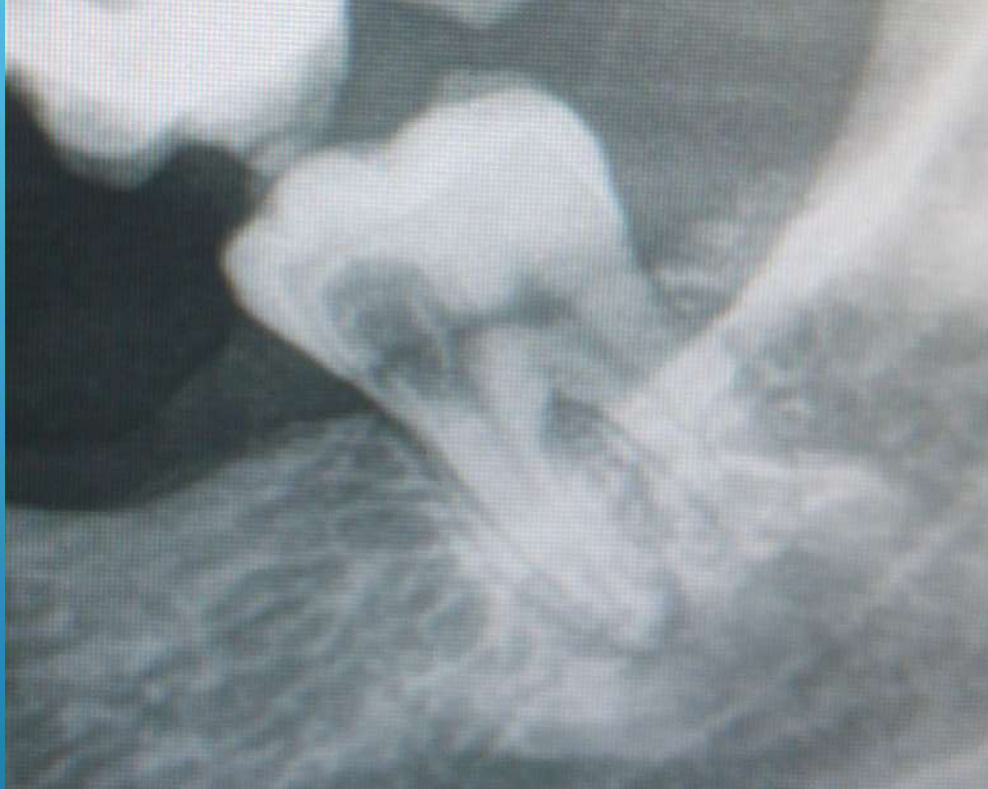



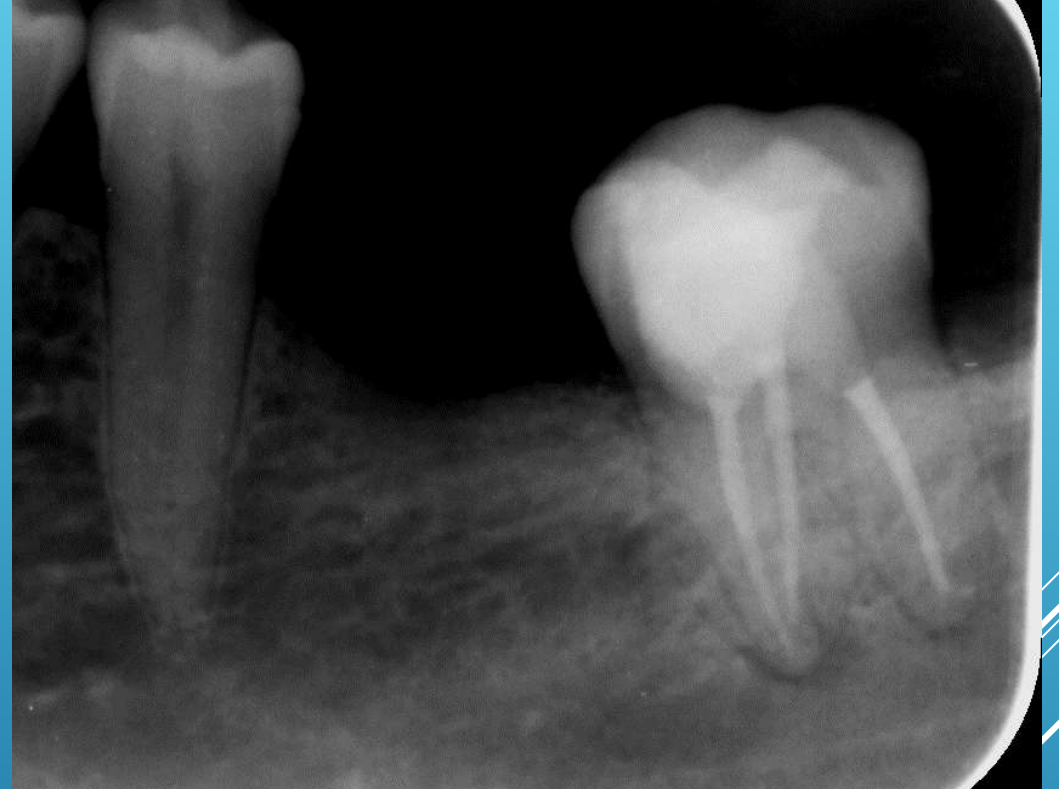Pre-op



Post-op

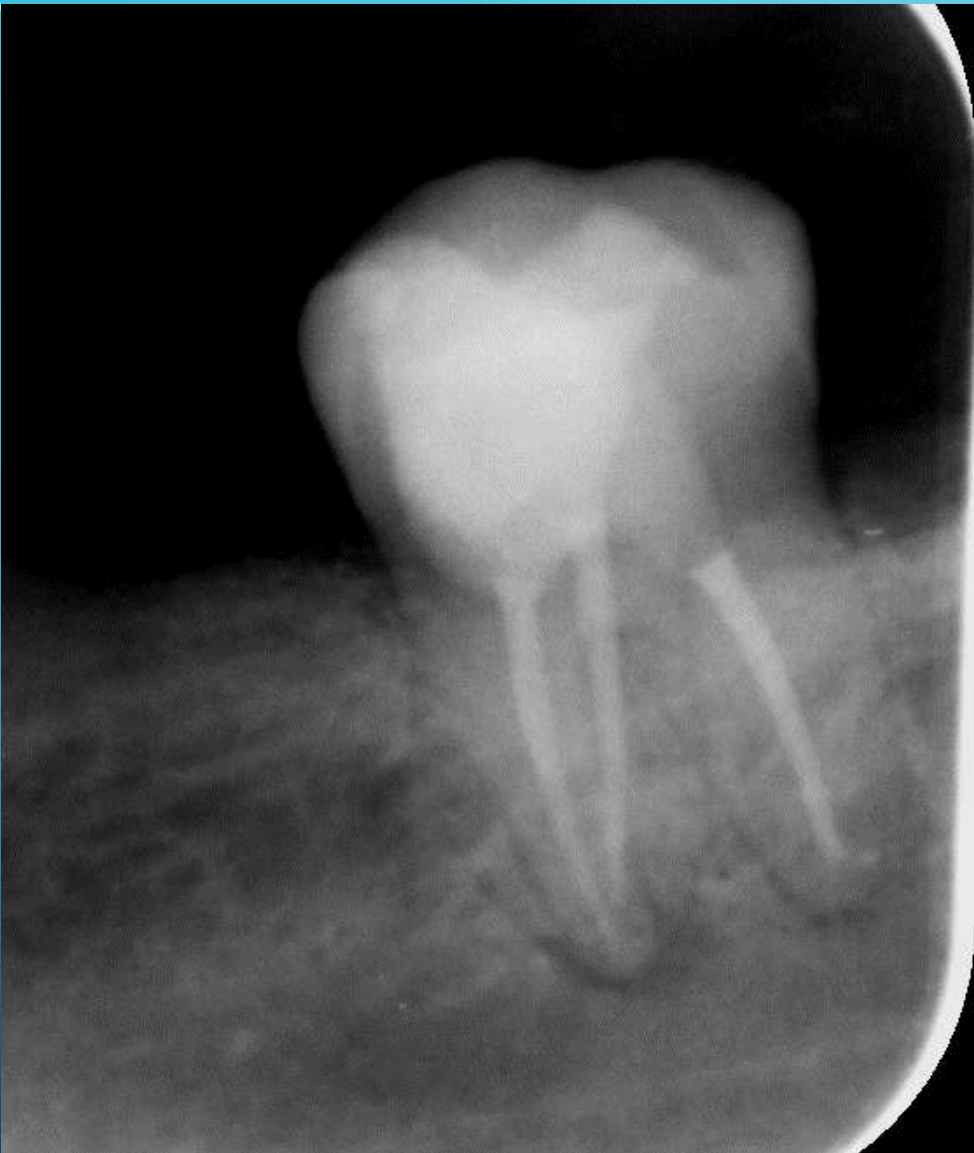

Pre-op

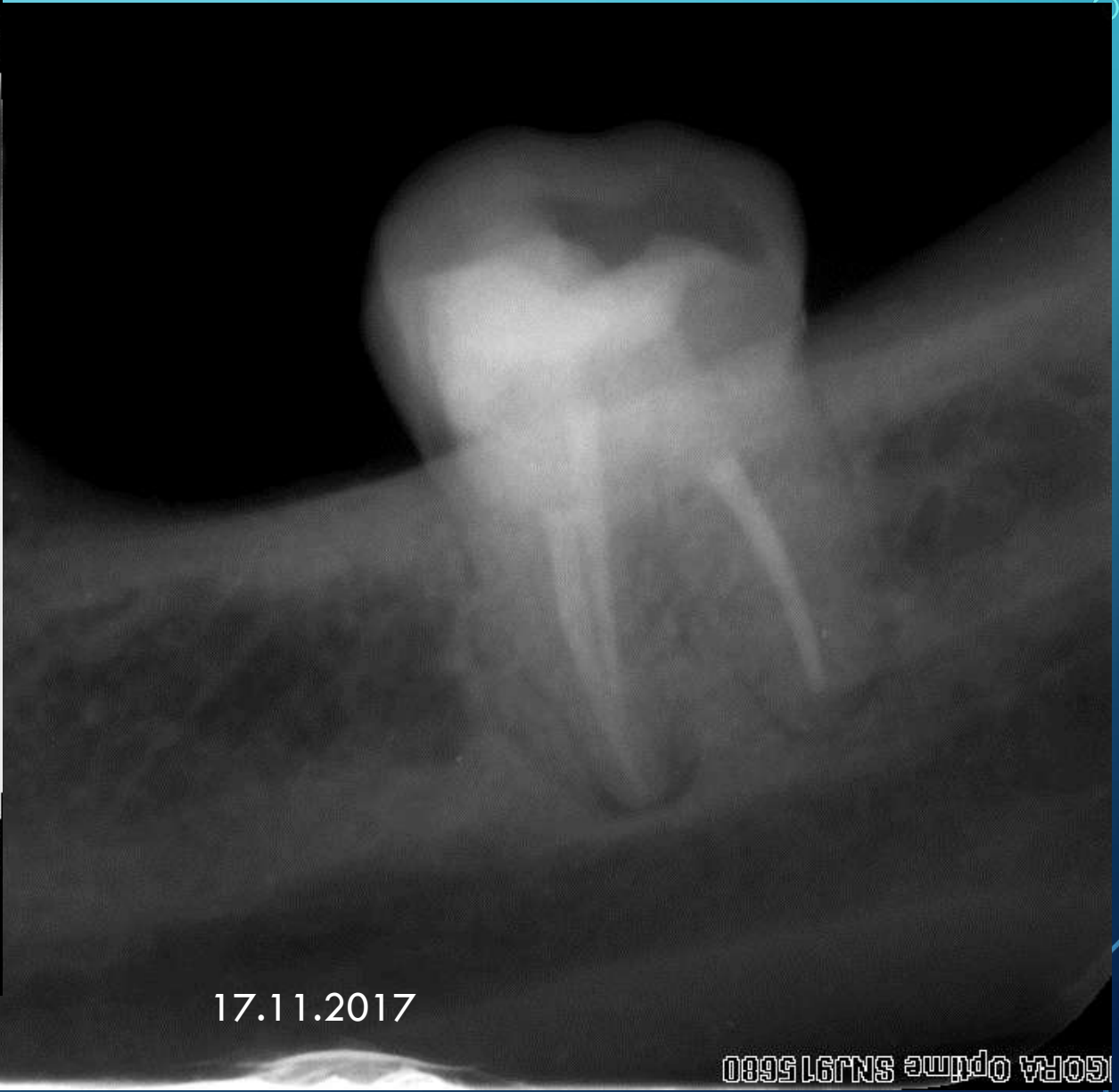

Post-op

DDS Jacek Bilbin



30.08.2017



17.11.2017

IGORA Optima S/N:1580