

PARTIAL PULPOTOMY

Right central incisor with complicated crown fracture

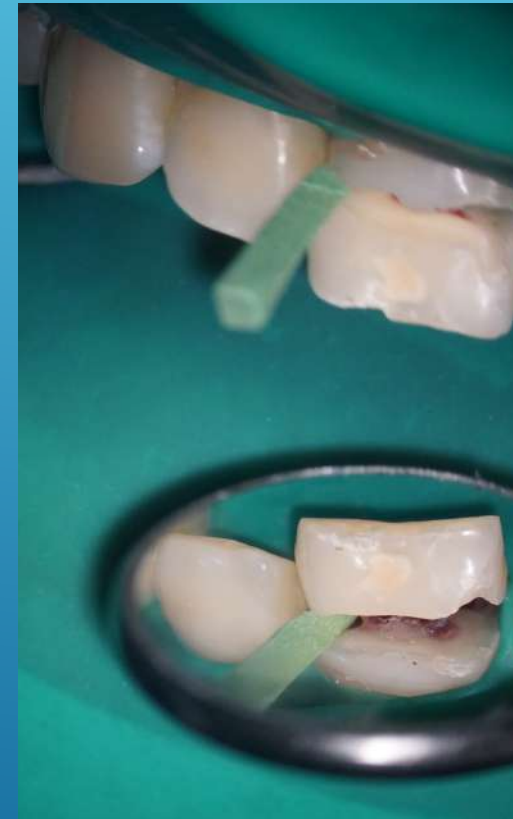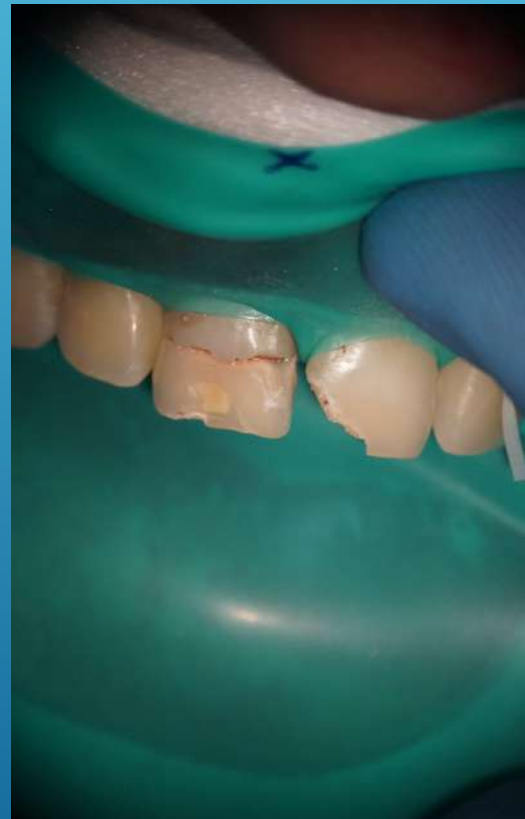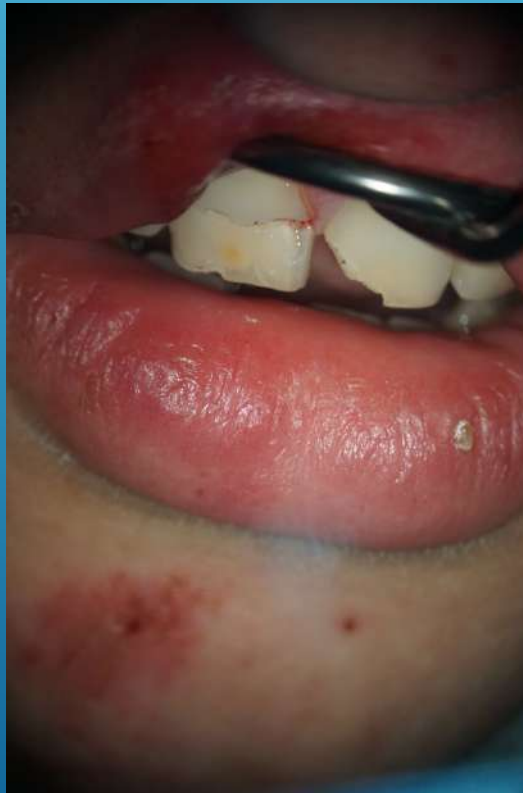DDS Jacek Bilbin

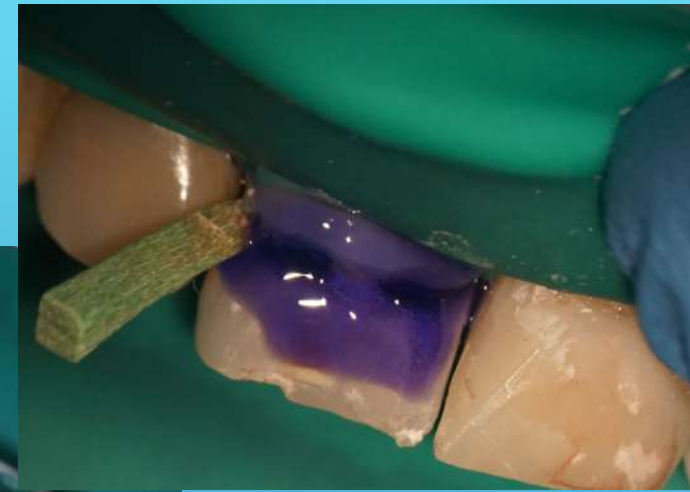
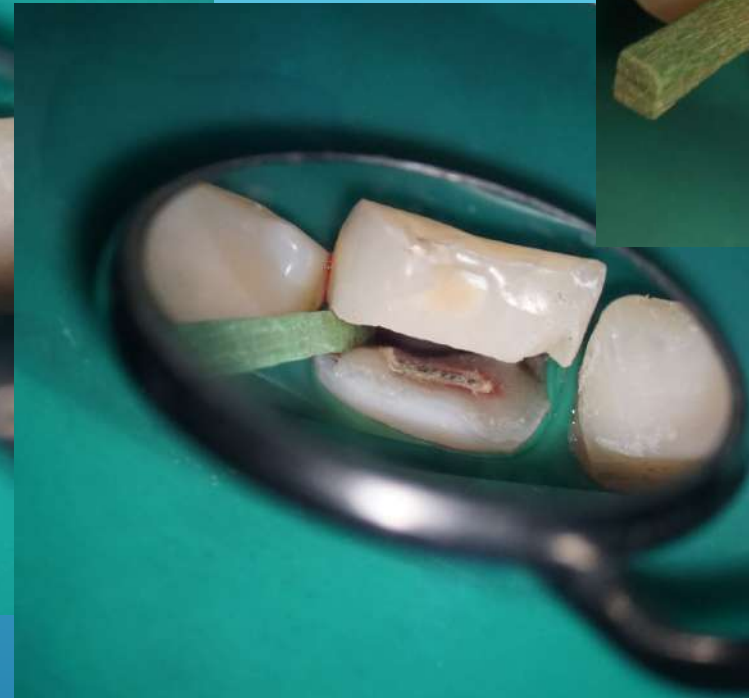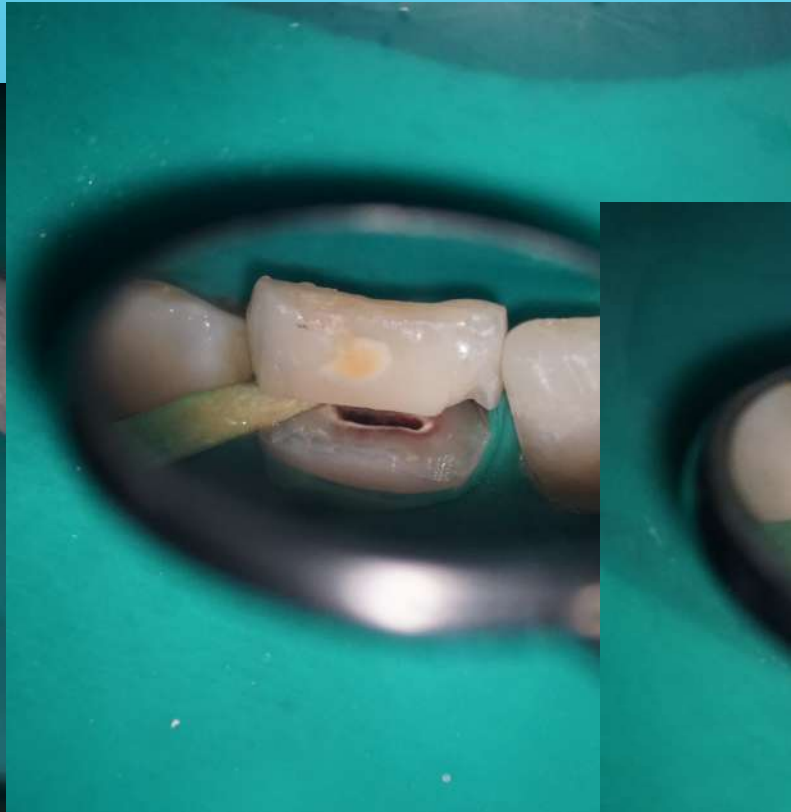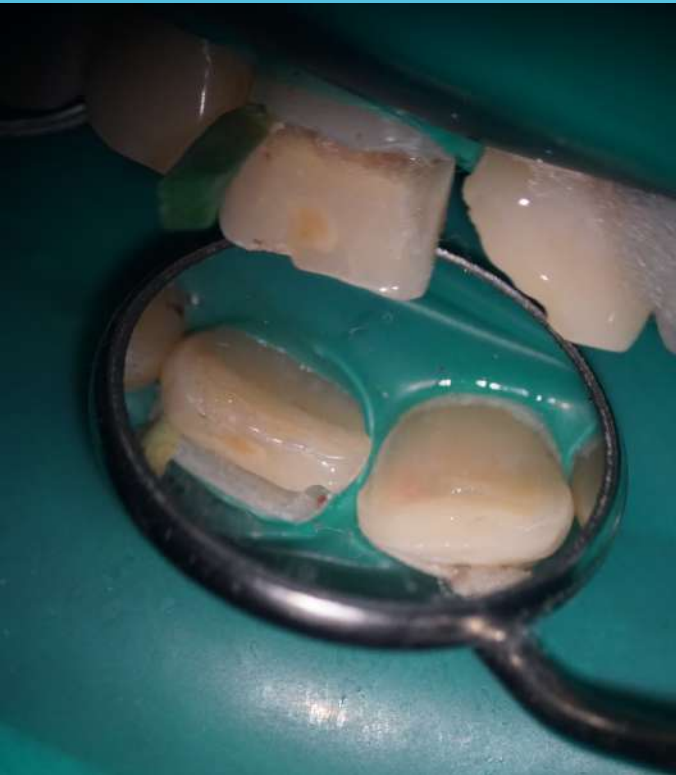Patient 17 years old

Patient had a bike accident 10 hours earlier.

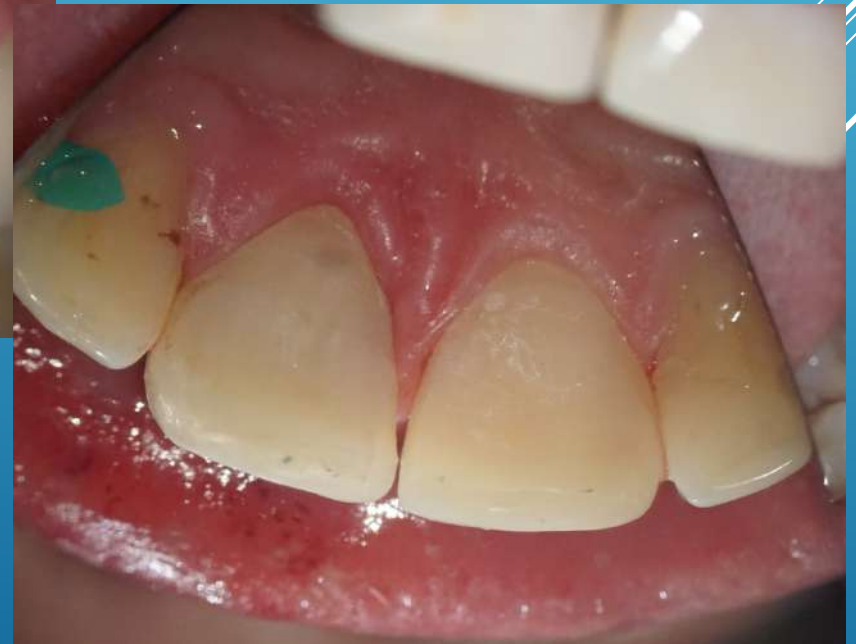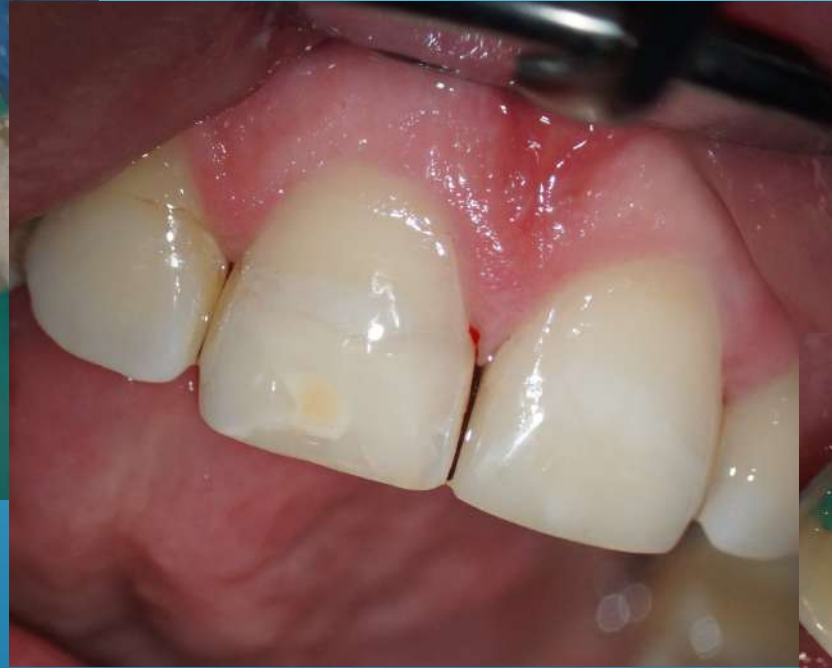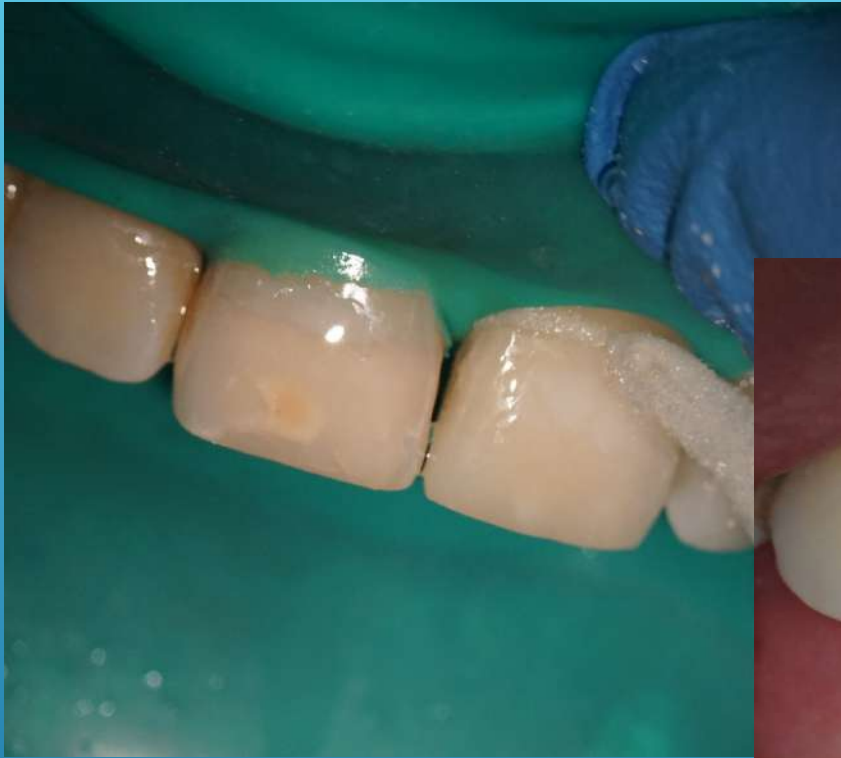11 Fractura coronae dentis cum denudatio pulpae.

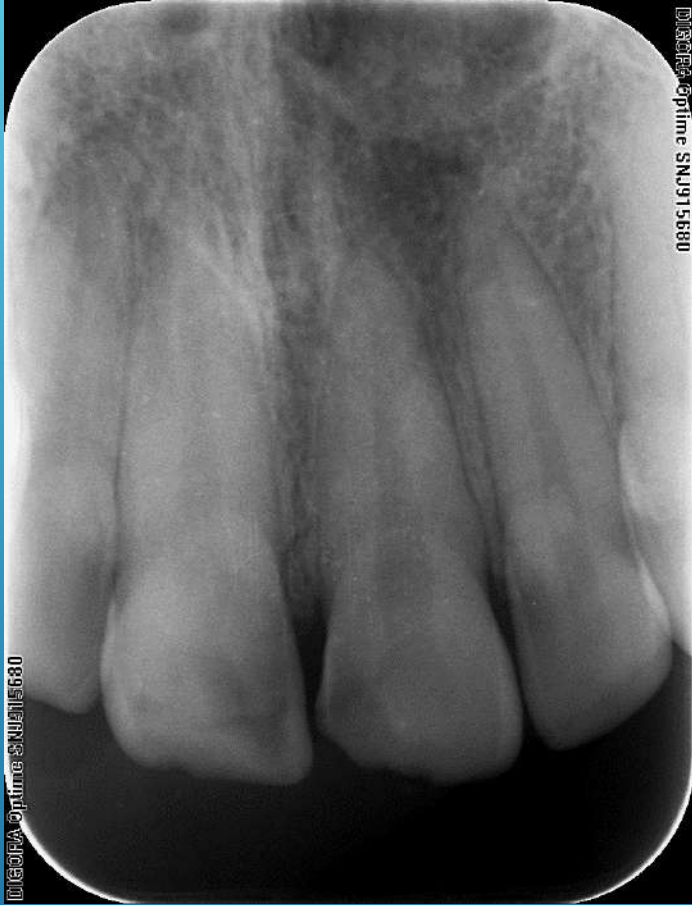21 Fractura coronae dentis sine denudatio pulpae.



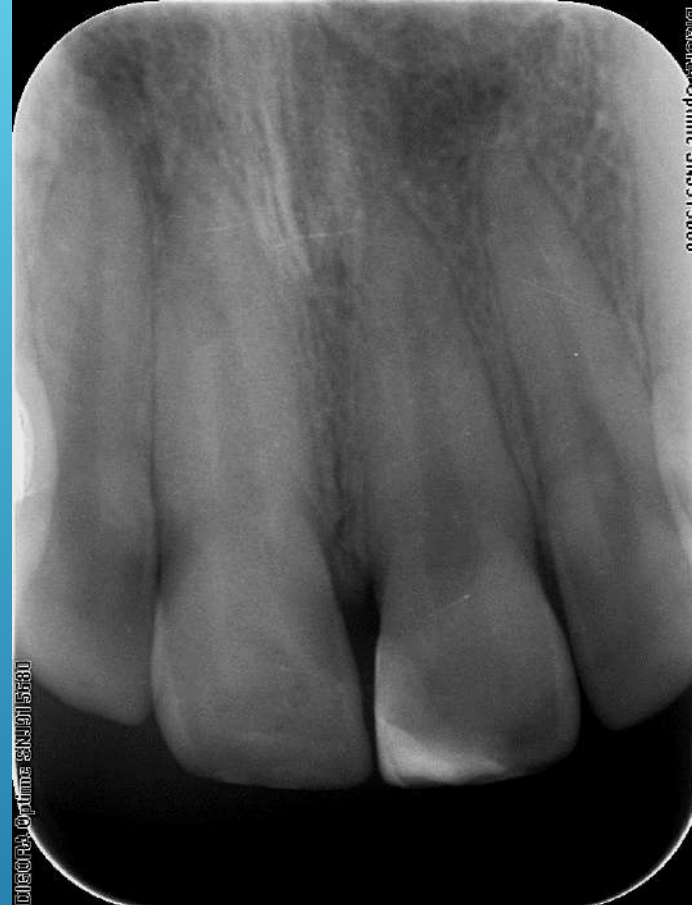

Anesthesia is administered , a rubber dam is placed and superficial disinfection is performed . Partial pulpotomy , Pro Root MTA is placed on the pulp. Total Etch , OptiBond -FL , Enamel Plus HRi



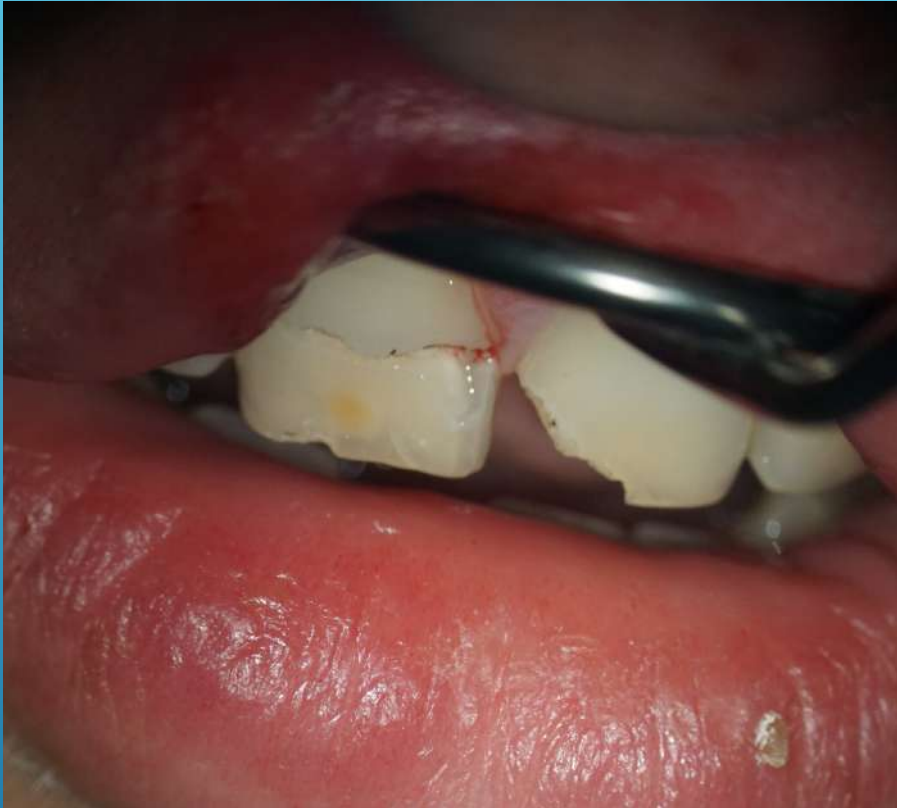

Pre-op

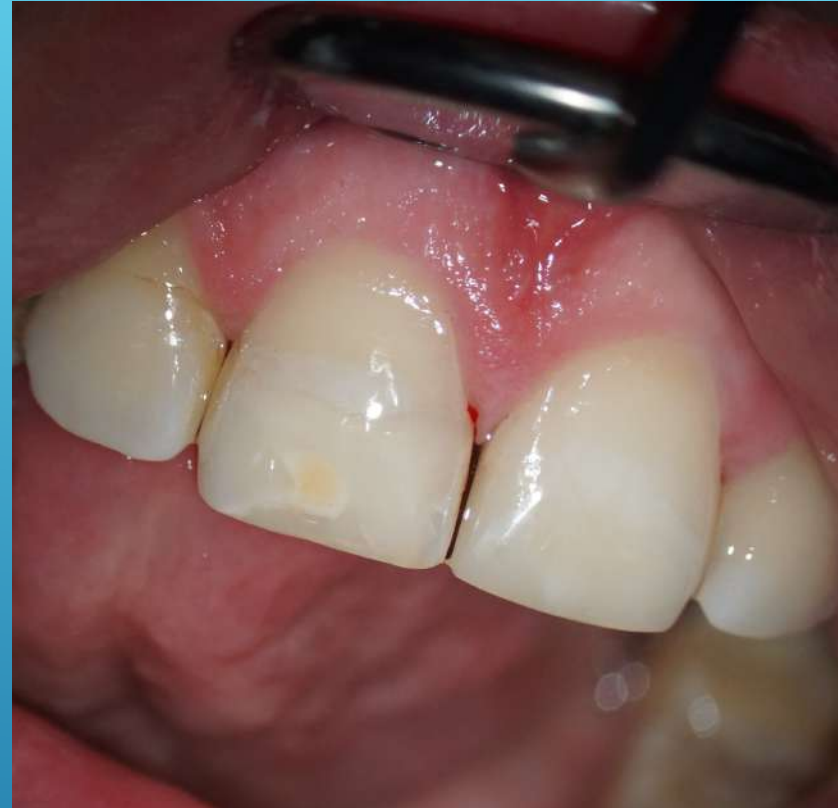

Post-op





Pre-op



Post-op

DDS Jacek Bilbin