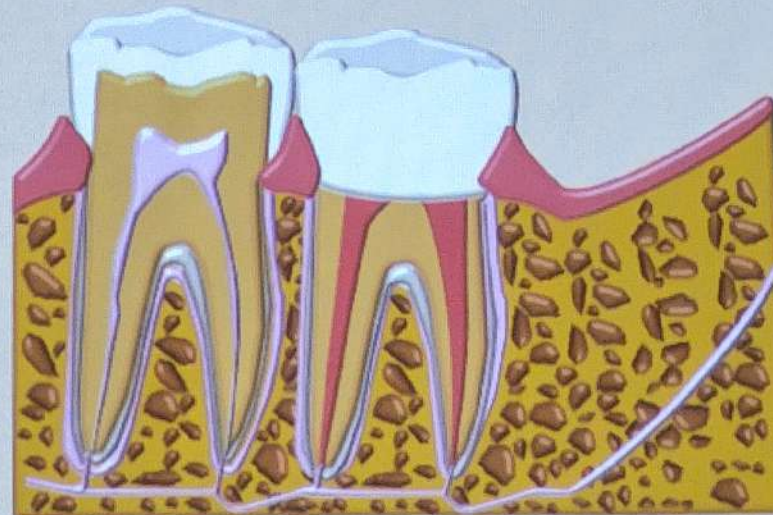




Planowa replantacja

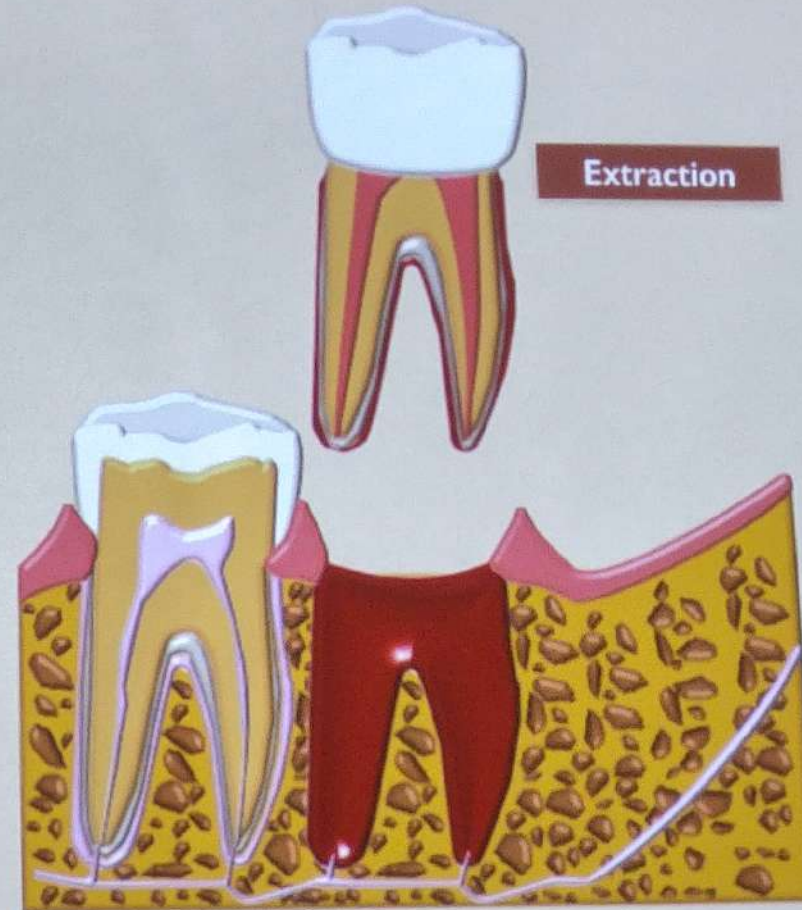
Ogólne zasady

Intentional Replantation



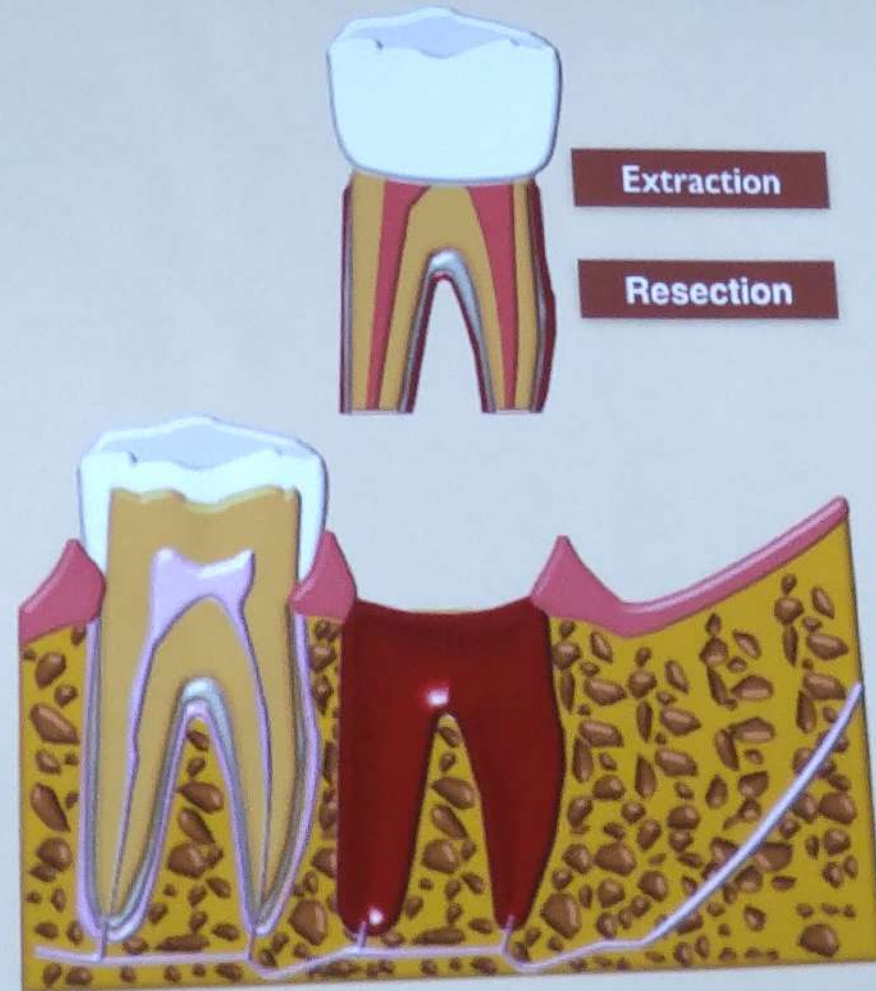
Barrett & Kenny, Endod Dent
Traumatol 1997

Intentional Replantation

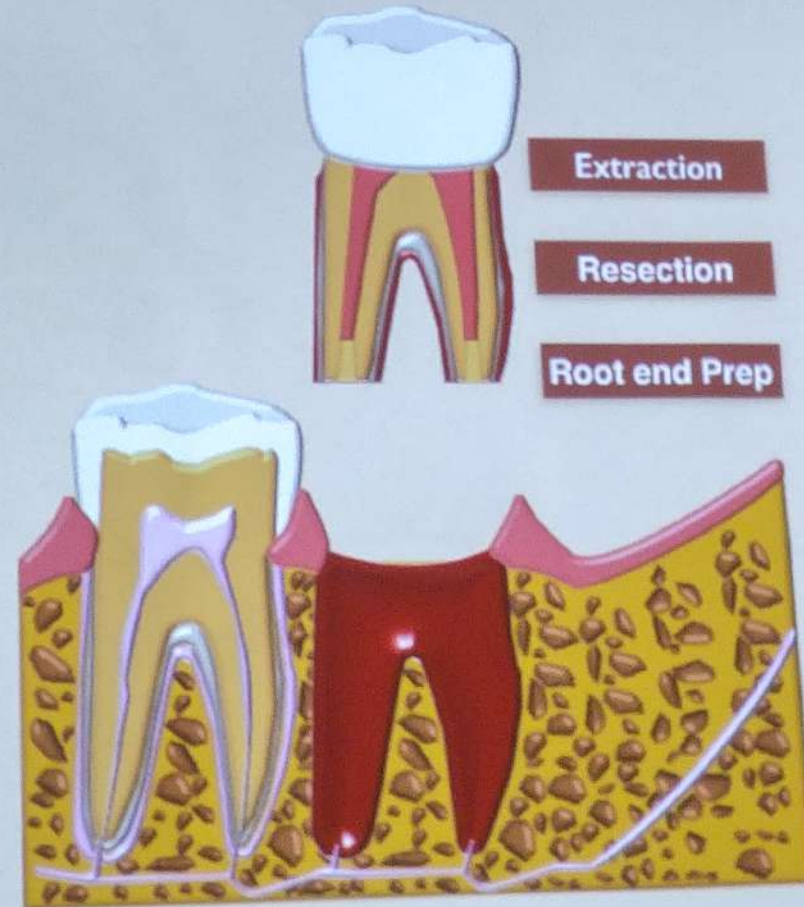


Barrett & Kenny, Endod Dent
Traumatol 1997

Intentional Replantation



Intentional Replantation



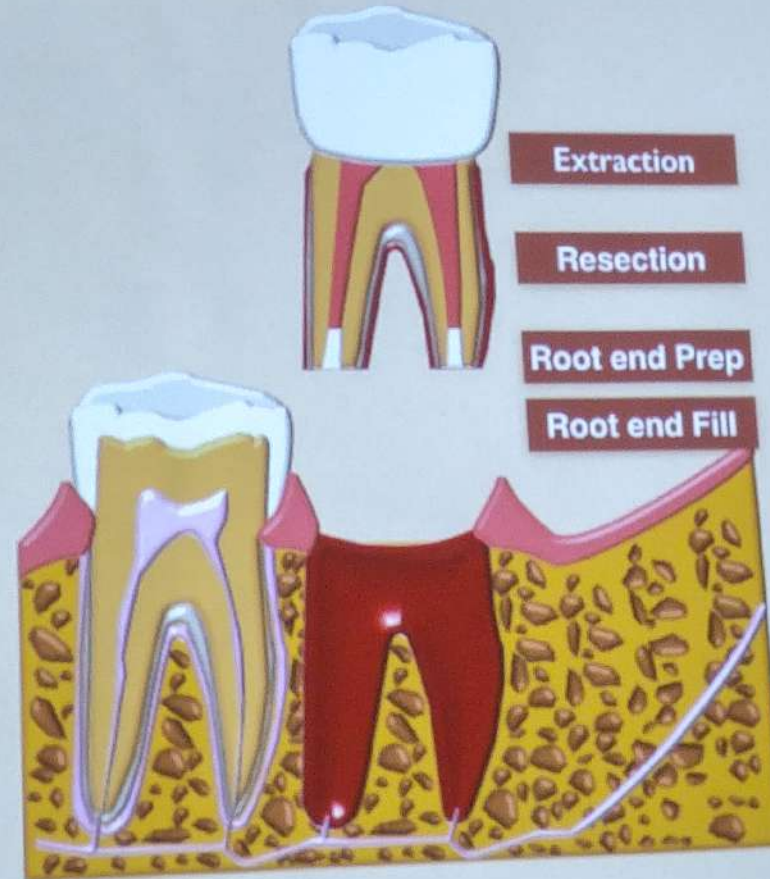
Barrett & Kenny, Endod Dent
Traumatol 1997

Intentional Replantation



TIME IS PRECIOUS!!!

Every effort should
be made to replant
the tooth within
10 to 15 minutes



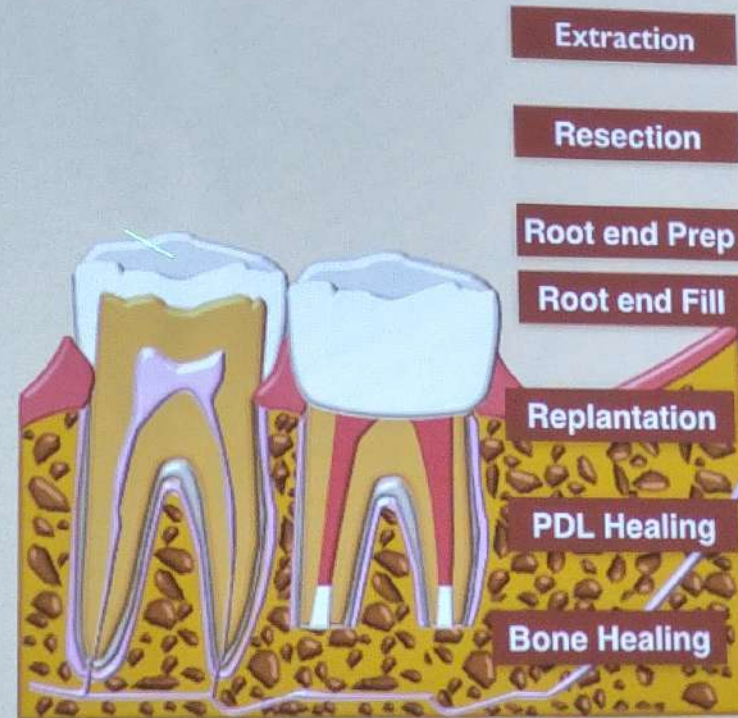
Barrett & Kenny, Endod Dent
Traumatol 1997

Intentional Replantation



TIME IS PRECIOUS!!!


Every effort should be made to replant the tooth within 10 to 15 minutes



Distance Between the Root Apex and the Outer Surface of the Buccal Cortical Plate in Mandibles

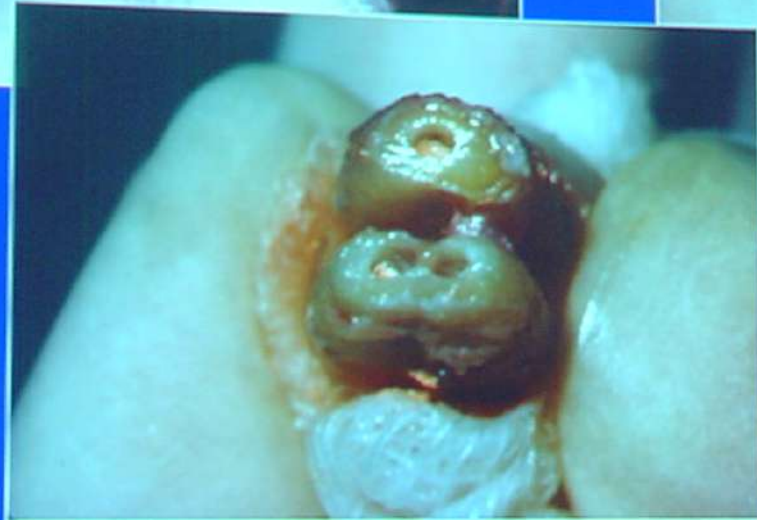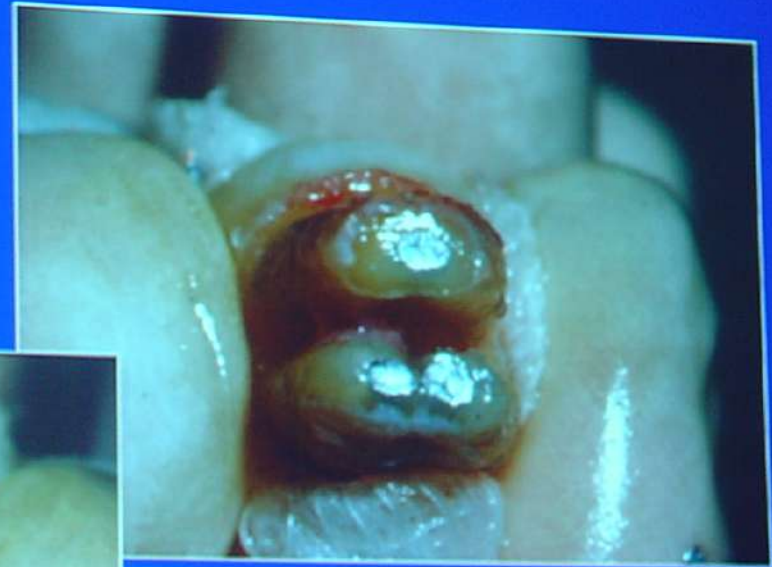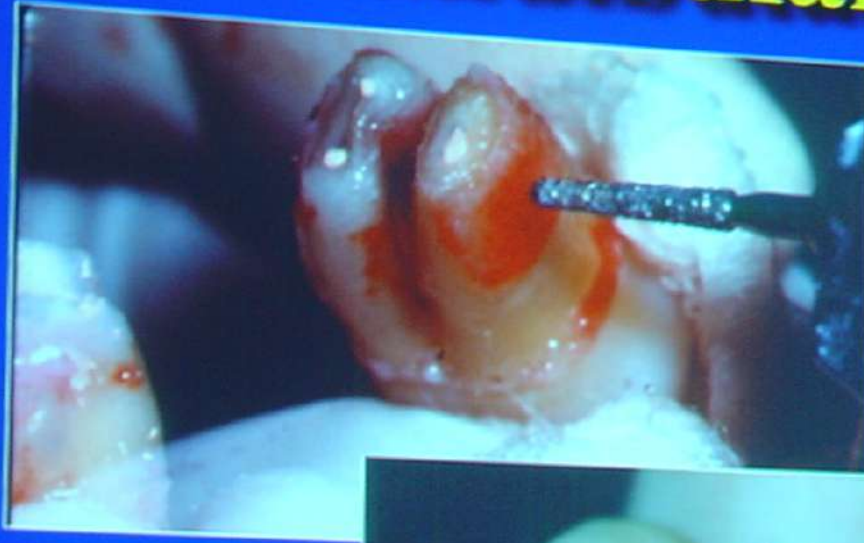CT study: 66 patients (1806 teeth)

Excess amount of bone reduction in the 2nd molar region



— Intentional Replantation —

Mandibular Second Molar

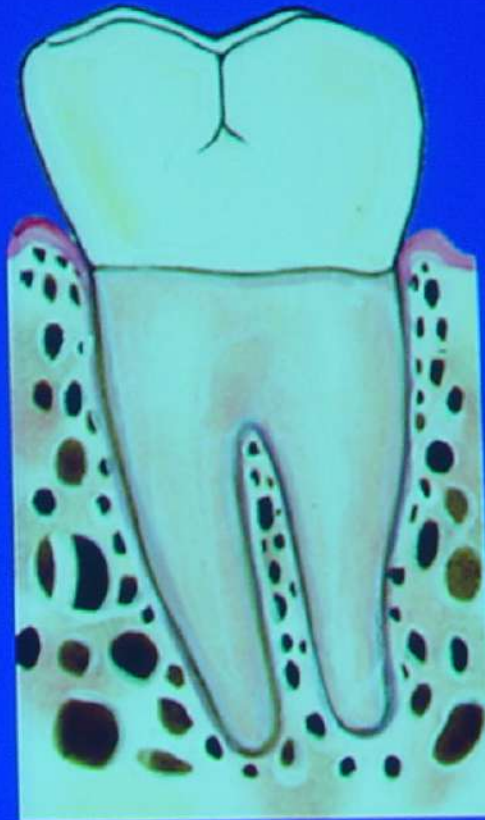

Intentional Replantation

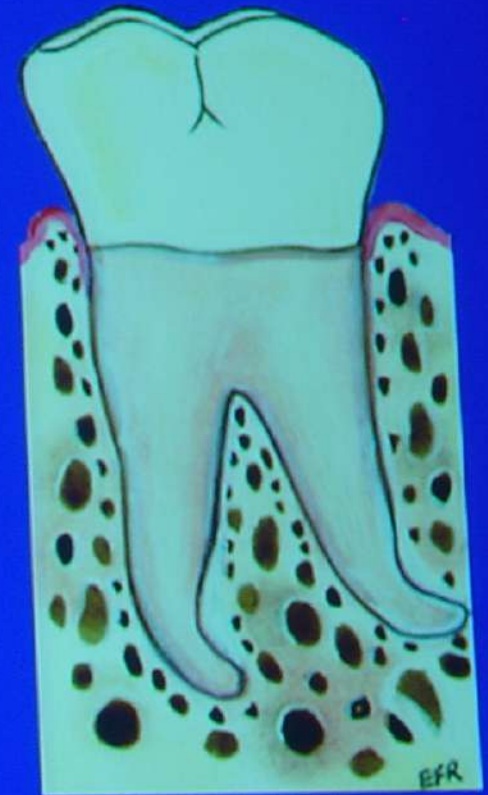
**Good / Bad
Candidate**




**Good
Candidate**




**Bad
Candidate**

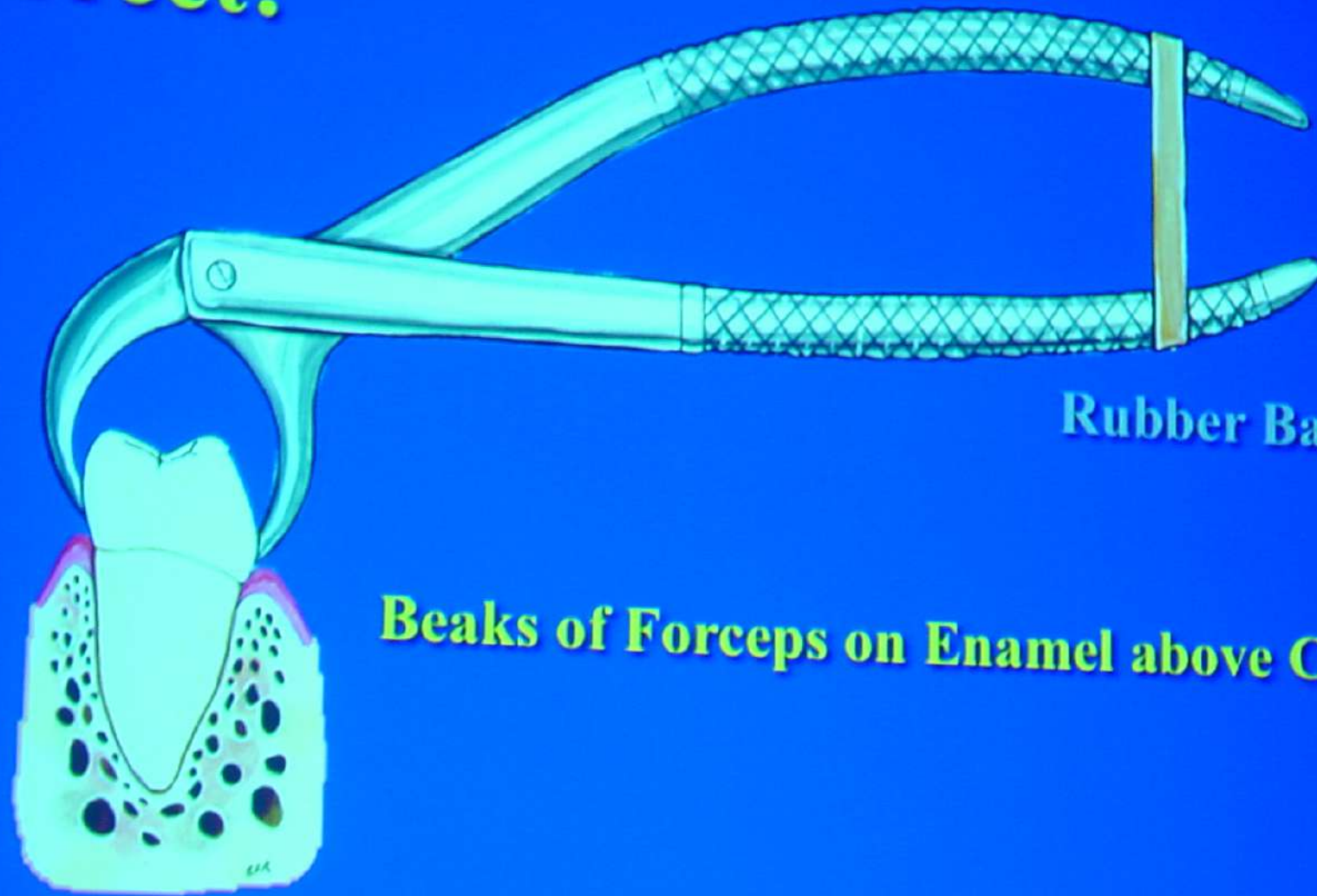




Recommendations

- **Keep forceps off cementum**
 - **Maintain viability of PDL**
 - **Keep extra-oral time short**
 - **Avoid curettage of socket**
 - **Splint only when necessary**
- 

Correct!



Rubber Band

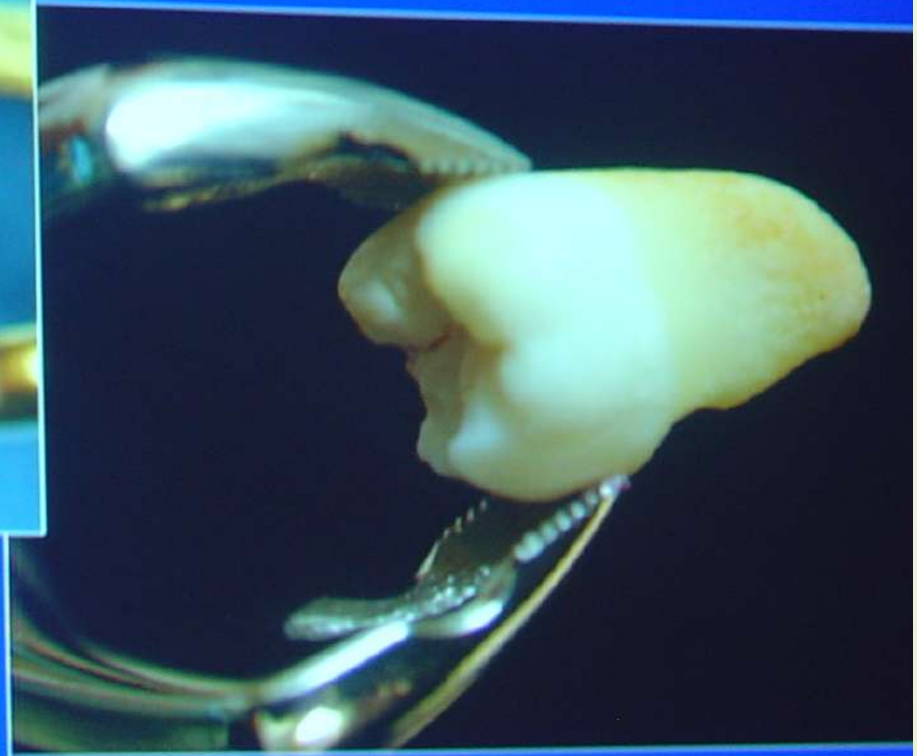Beaks of Forceps on Enamel above CEJ

Ögram System

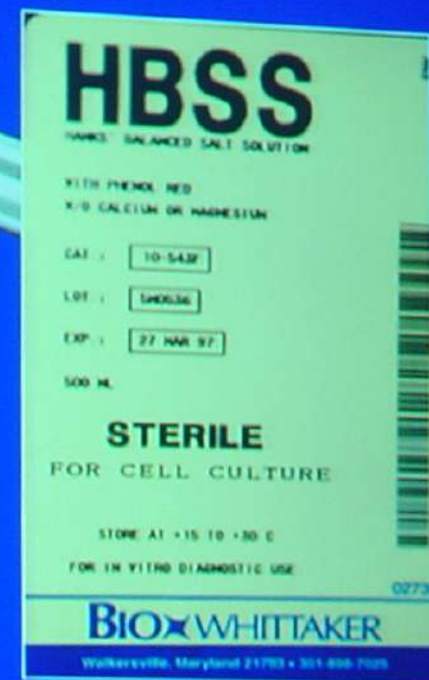
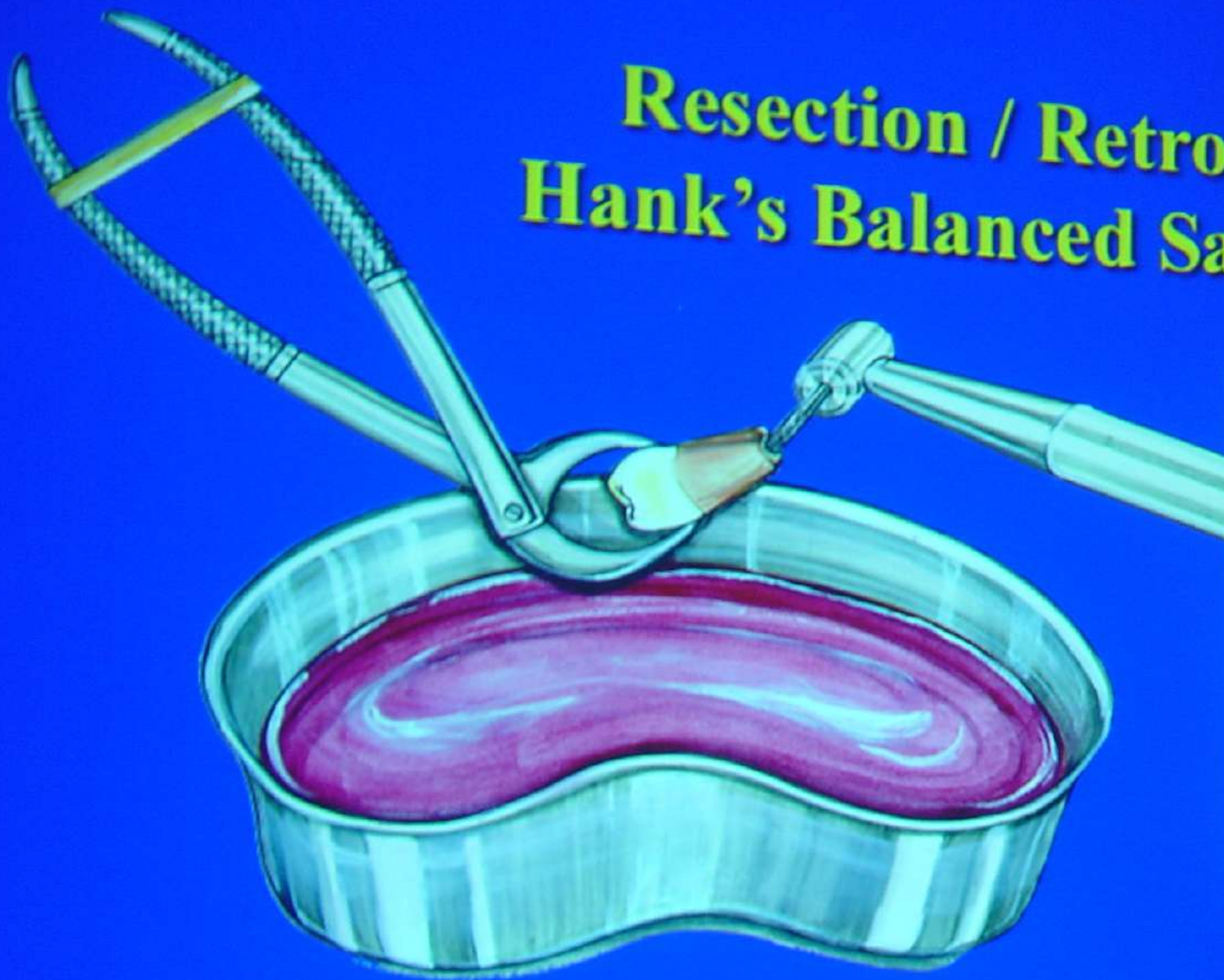
Karl Schumacher: 800-523-2427
#10AS (Max) #222AS (Mand)




Serrated edges



Resection / Retro-Prep in Hank's Balanced Salt Solution

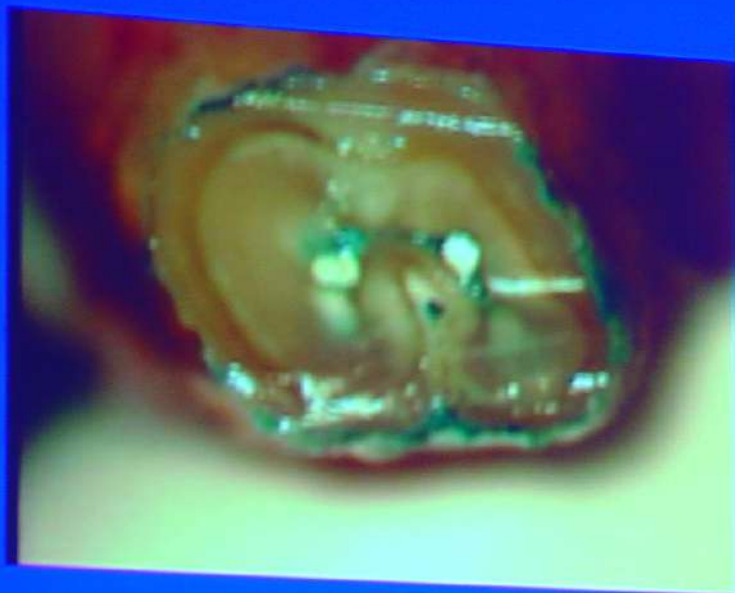


301-898-7025
Cambrex Bio Science

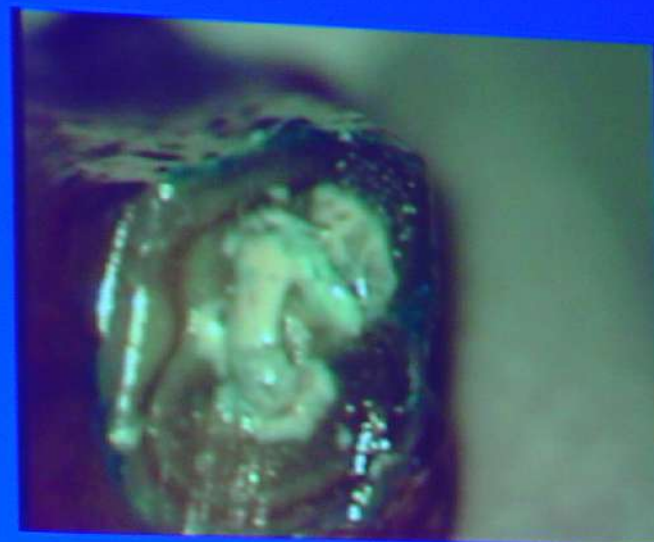

Time	Healing Events
3 days	Separation line in the middle of the PDL is mediated by blood clot
7 days	Attachment of the junctional epithelium is re-established Gingival collagen fibers reunited Continuity of the severed PDL re-established with connective tissue
1 month	PDL has a normal appearance but the connective tissue is not yet mature
4 months	Re-establishment of a functionally oriented PDL

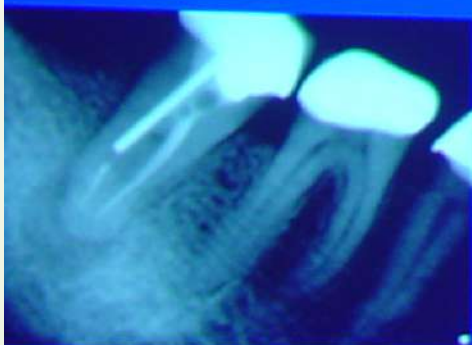
Andreasen JO. *Swed Dent J* 1980; 4: 101-10.



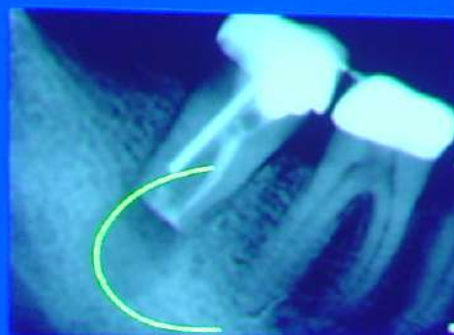Apico



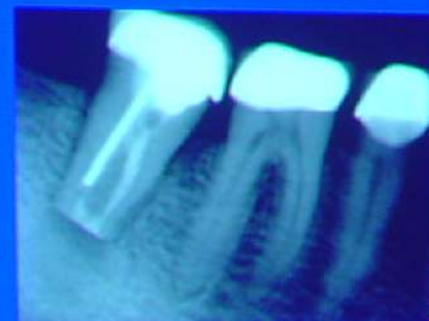MTA



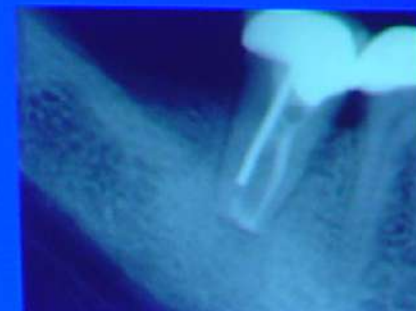Preop



Postop



1 mon



6 mon

Then

- **Tooth held in gauze**
- **Socket curettage**
- **Visual inspection**
- **Every case splinted**
- **Narcotic pain medication,
Antibiotics**