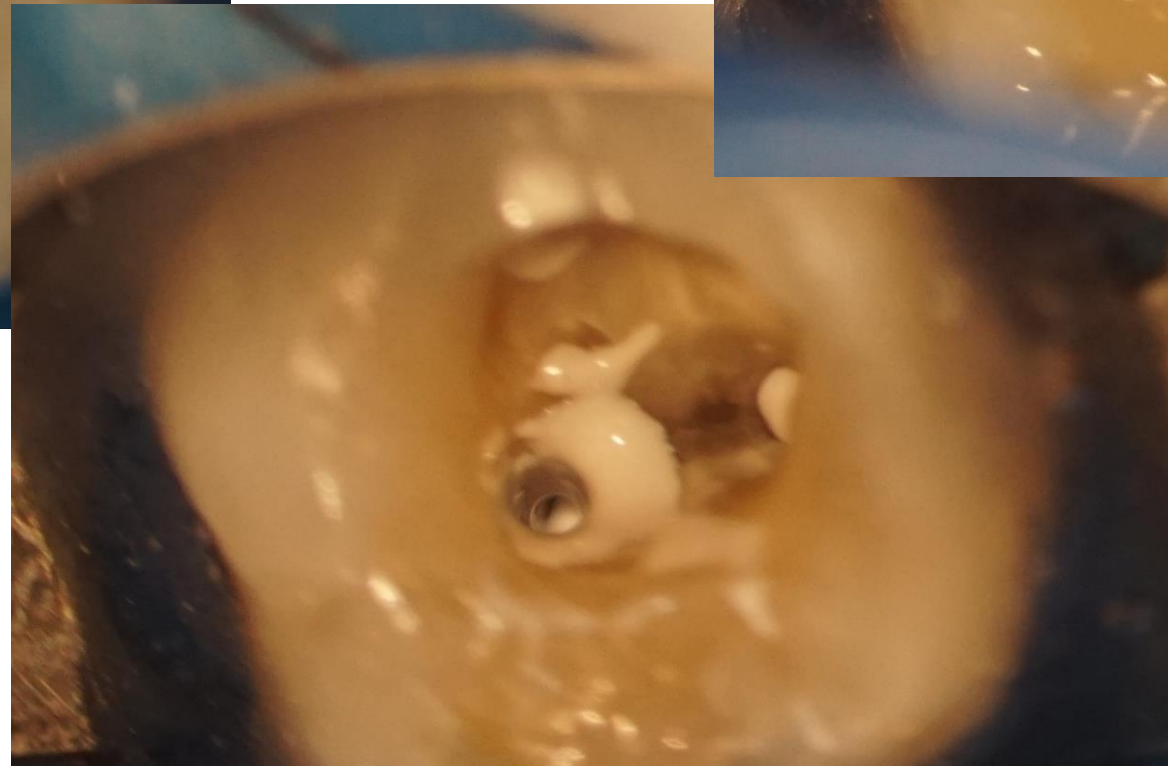
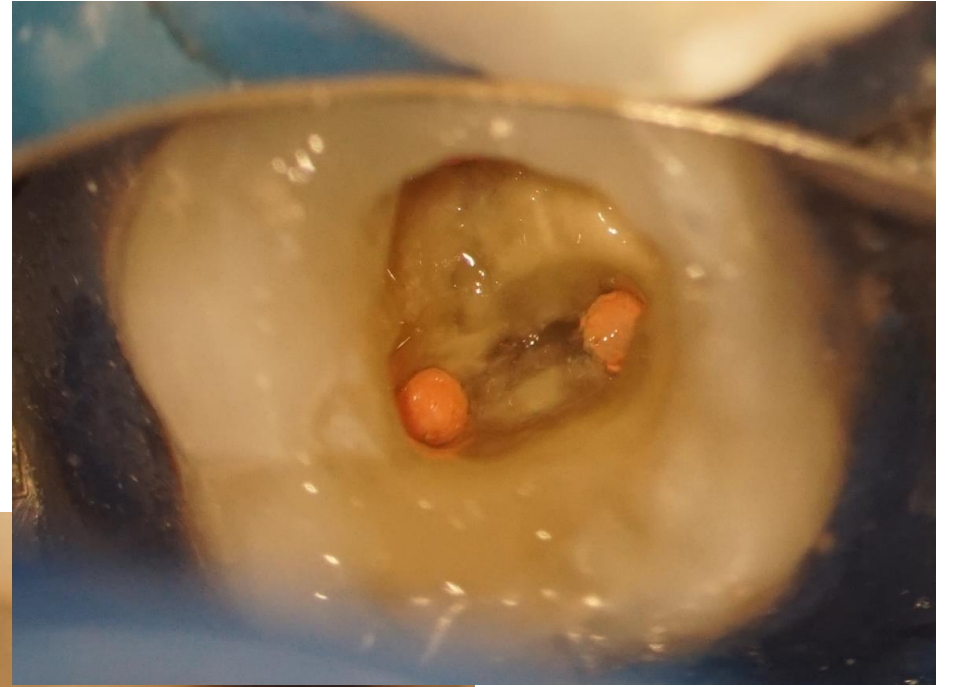
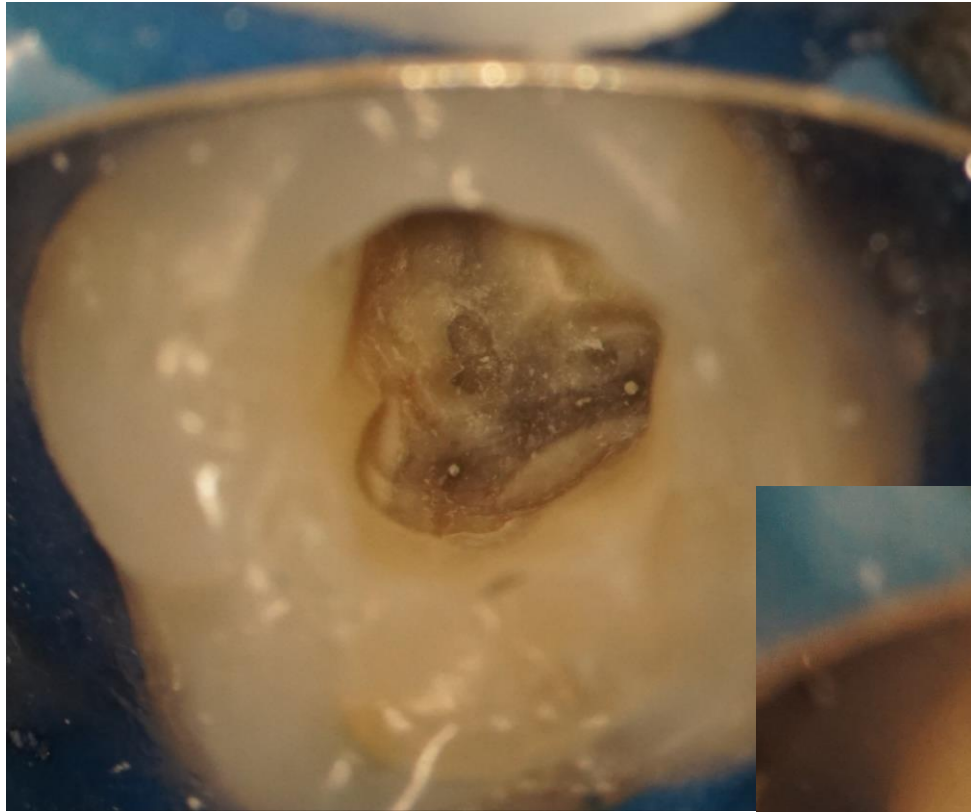


TotalFill

FKG swiss endo

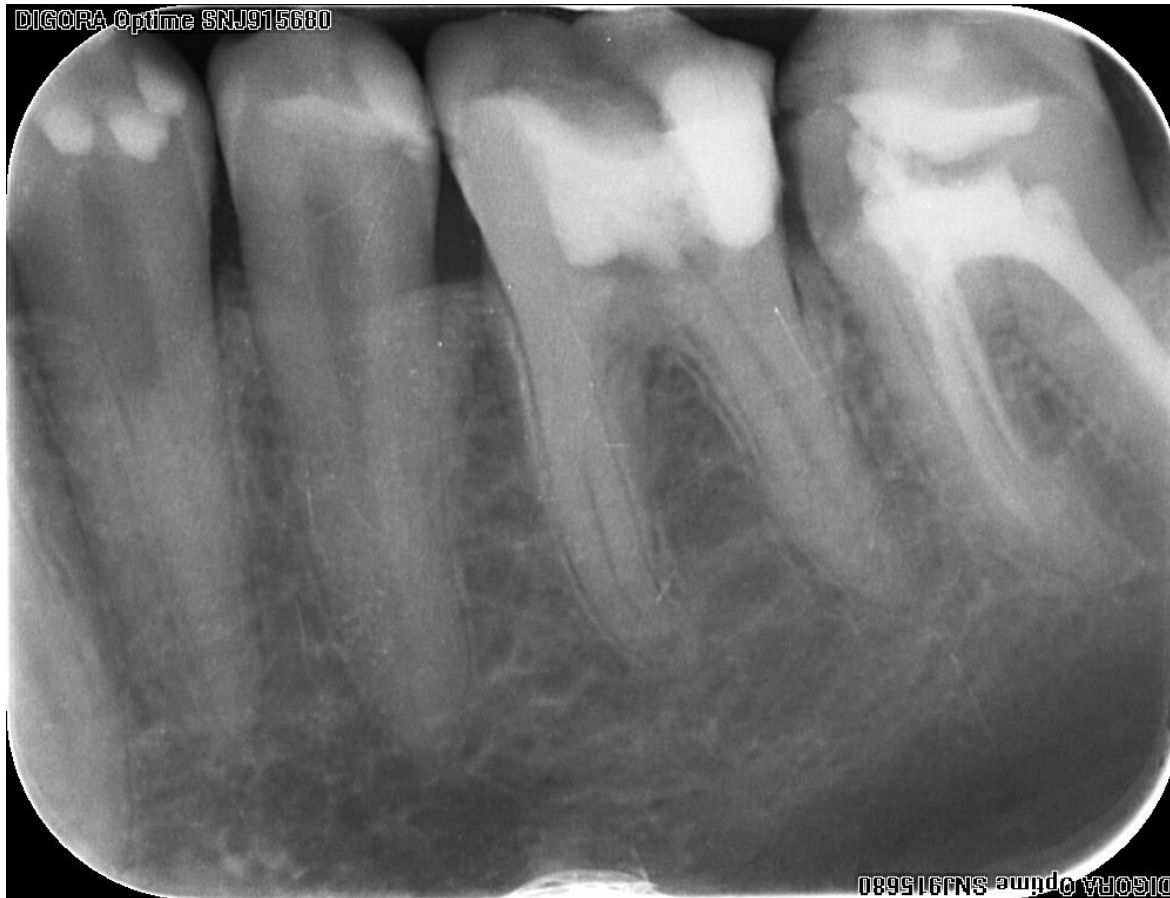Clinical application

Dr Jacek Bilbin

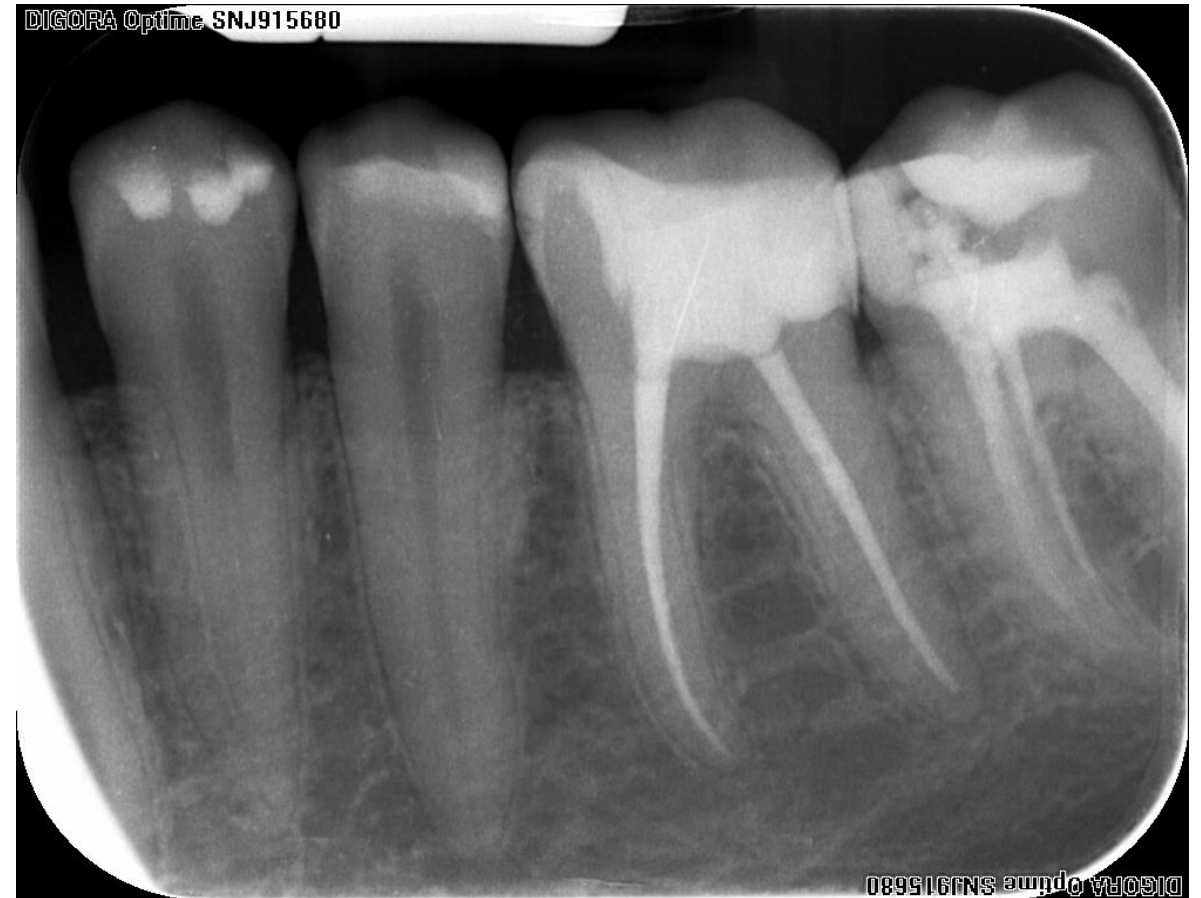

**Obliteration of root canals
Preparation D- Finder Mani,
Race ISO10 ,ScoutRace 15,20
XP-endo shaper
,finisher.Obturation TotalFill
sealer.**

Obliteration of root canals

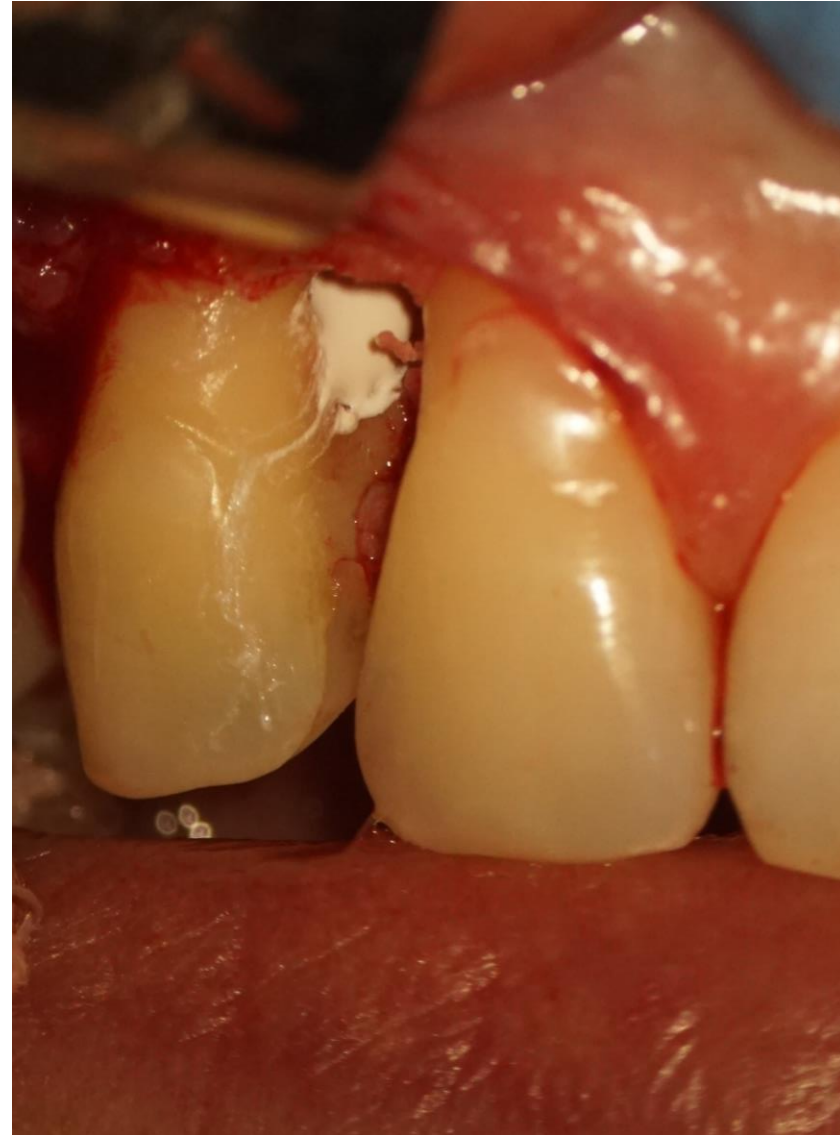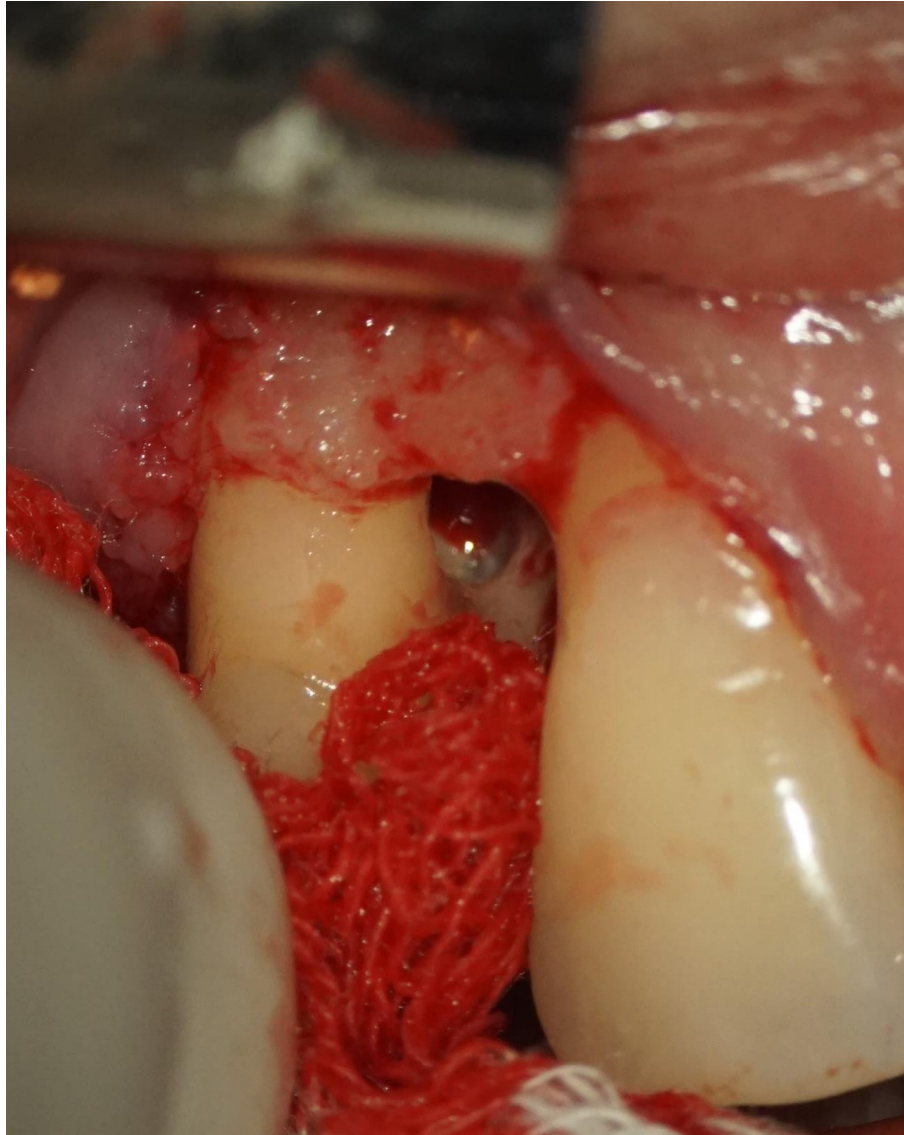


Pre-op

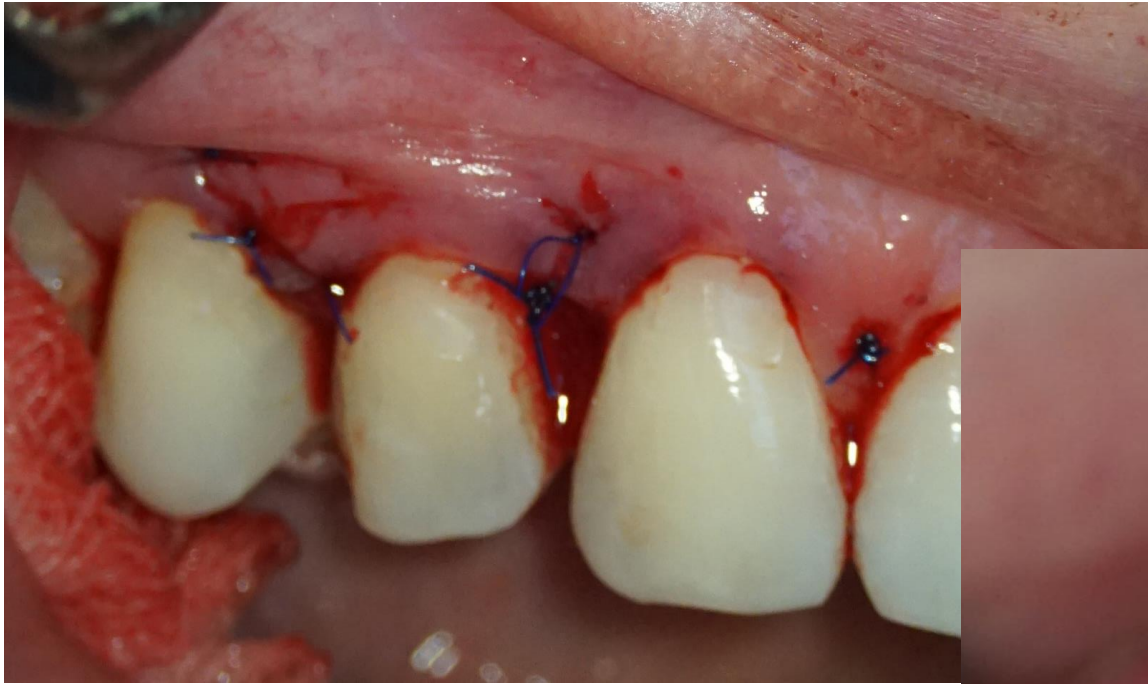


Post-op

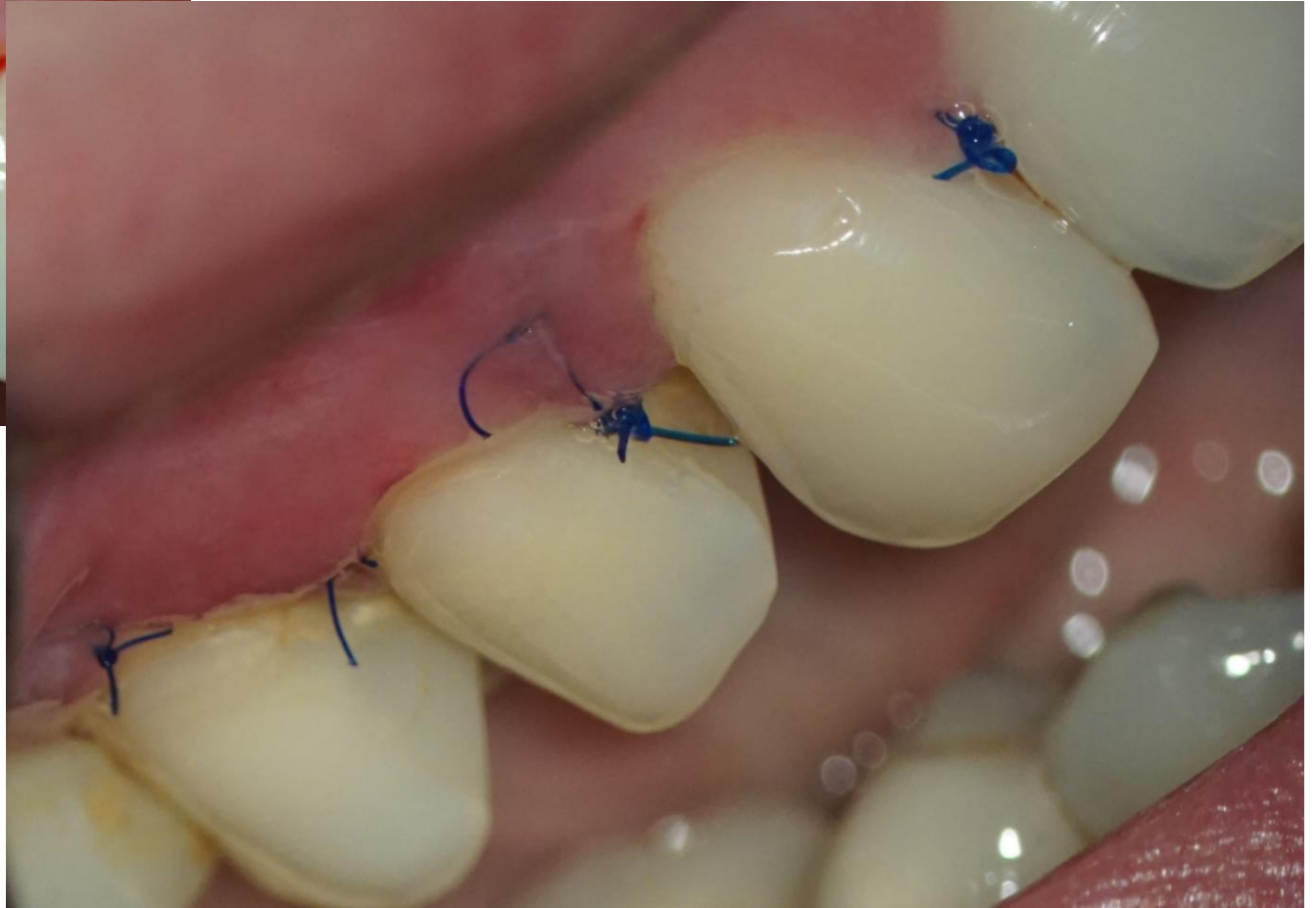Invasive cervical resorption



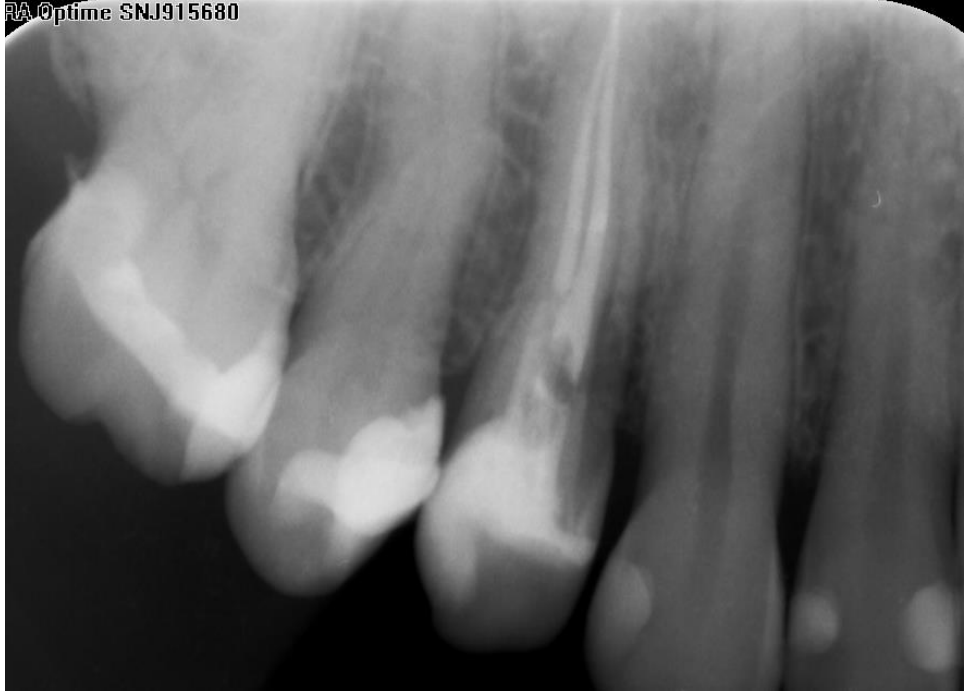Tooth 14 , Invasive cervical resorption , TotalFill RRM, sutures 6,0



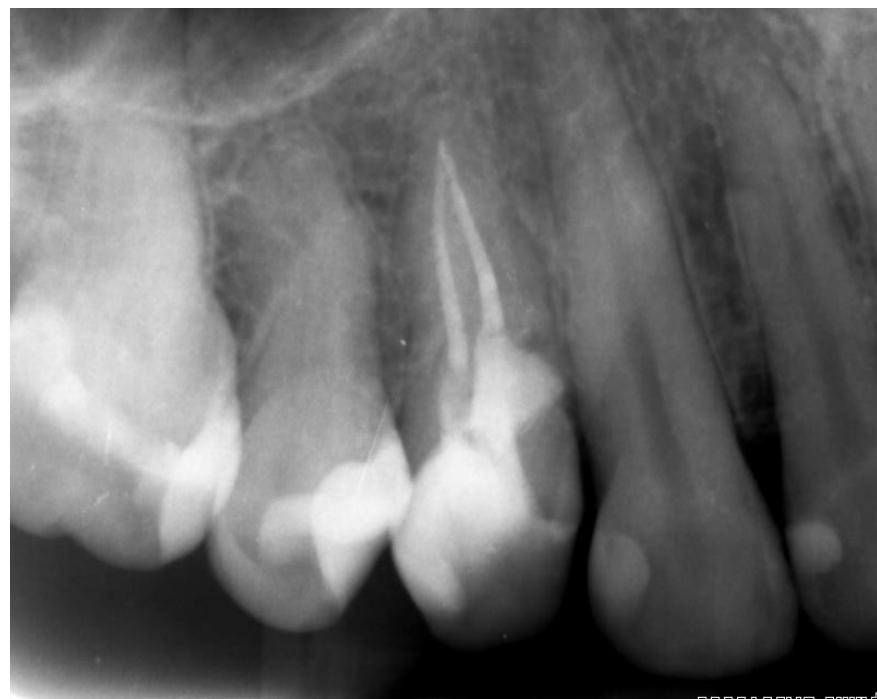Post-op



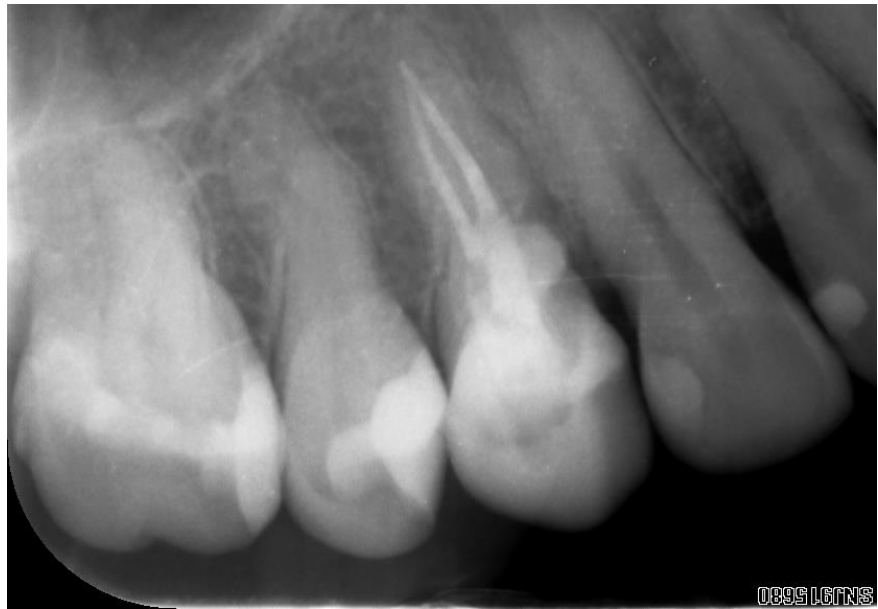
1 week later



Pre-op



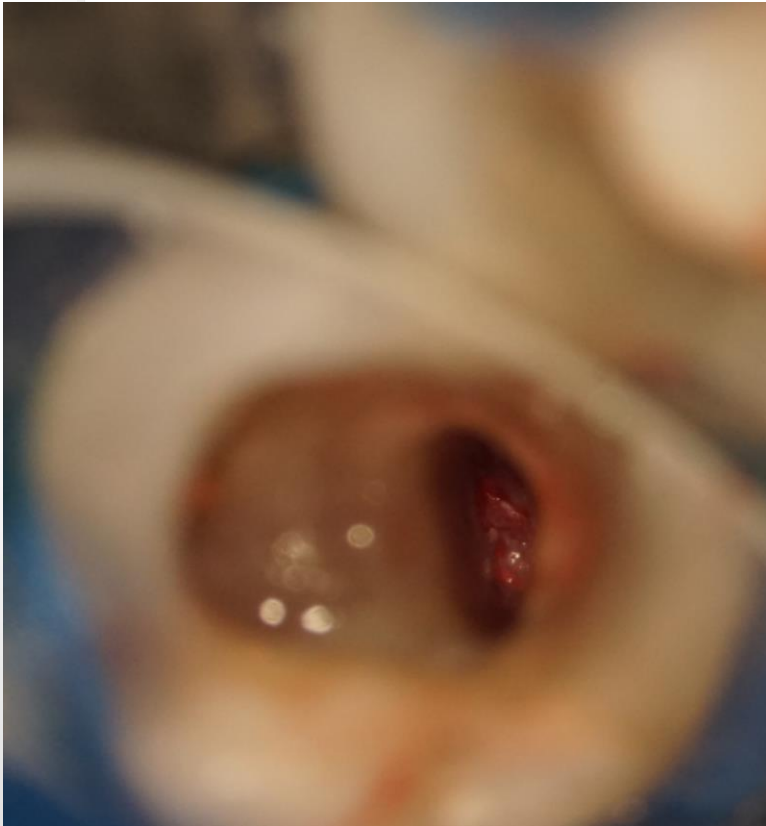
Post-op



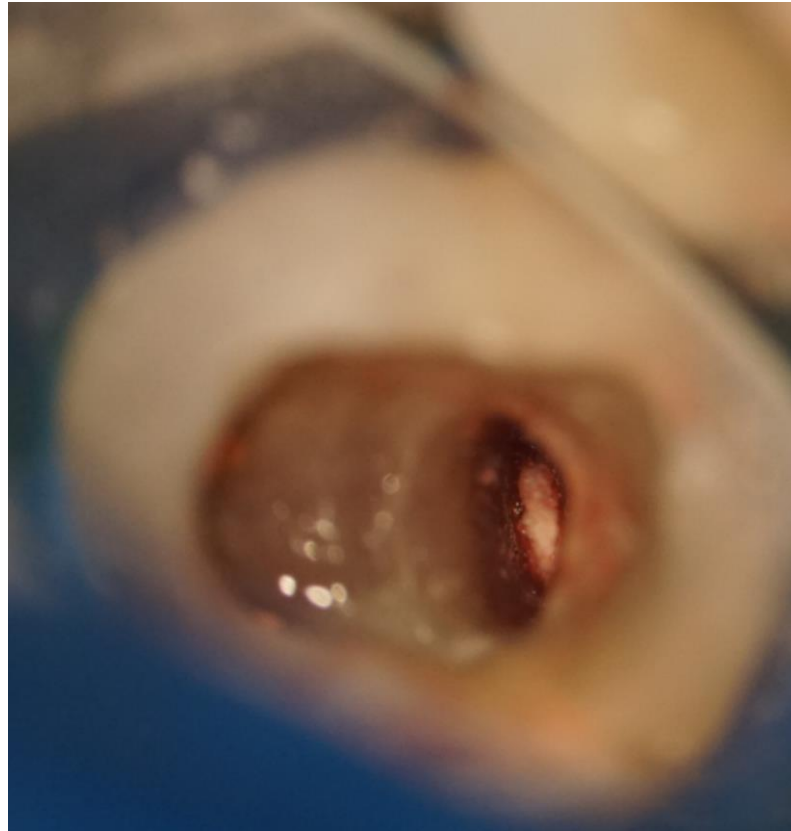
3 months later

Dr Jacek Bilbin

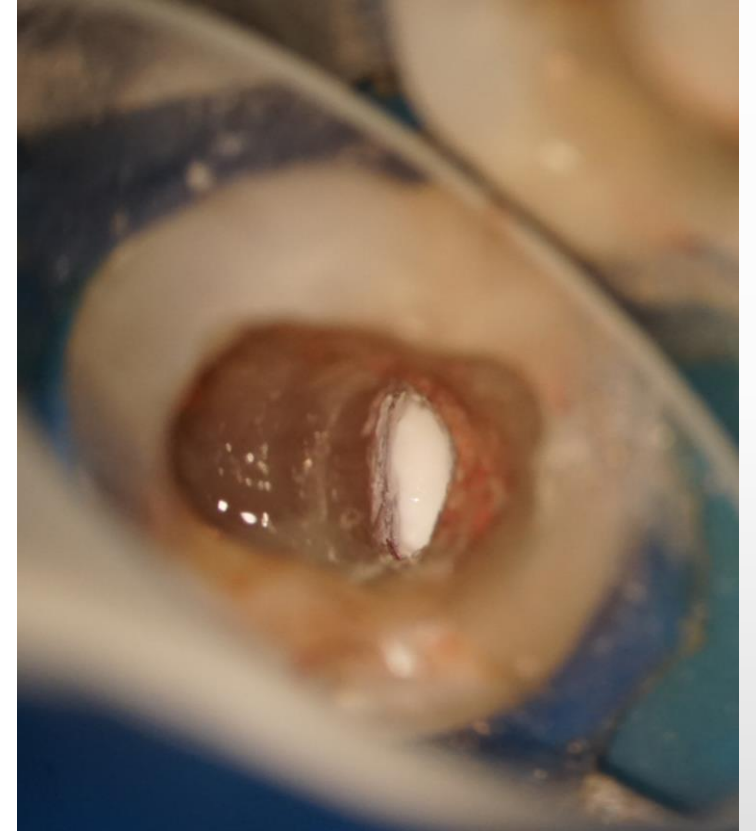
Filling the tooth canal with a wide apical opening.



Visible periodontium



Barrier from Parasorb (Resorba)



Filling from TotalFill RRM